



## ULTRASTRUCTURAL CHANGES INDUCED BY IMIDACLOPRID IN MALE ALBINO RATS

**S.SOUJANYA\***

*Department Of Veterinary Pathology College Of Veterinary Science,  
Rajendranagar, Hyderabad-500 030 (AP), INDIA*

### ABSTRACT

In the present study, ultrastructural alterations induced by oral administration of imidacloprid over 4 weeks was assessed in rats. Forty eight male sprague dawley rats procured from NIN and divided into four groups. Group 1 given with basal diet, group 2 orally gavaged with 80mg/kg/day imidacloprid, group 3 was treated with vitamin C at the rate of 10 mg/kg b.wt/day and group 4 was treated with both imidacloprid and vitamin C for 4 weeks. In group 2, Ultra thin sections of kidney has evidenced apoptotic nuclei, pleomorphic mitochondria and liver showed swollen nuclei, disrupted chromatin and rough endoplasmic reticulum. Testes revealed increased perinuclear space, disintegrated chromatin, degeneration of spermatids and brain revealed vacuolar mitochondria and apoptotic nuclei. A mild improvement was observed in group 4. In conclusion, these results suggest that exposure to imidacloprid in rats induced ultrastructural alterations and co-administration of vitamin C brought mild protection.

**KEYWORDS:** imidacloprid, ultrastructural changes, vitamin C



**S.SOUJANYA**

**Department Of Veterinary Pathology College Of Veterinary Science,  
Rajendranagar, Hyderabad-500 030 (AP), INDIA**

*\*Corresponding author*

## INTRODUCTION

Imidacloprid, a neonicotinoid insecticide, is extensively used in agriculture for control of the sucking insects and coleopteran beetles<sup>1</sup> and also used as foliar treatment for soil and for seed dressing<sup>2</sup>. In Veterinary Medicine, it is used as flea control agent on dogs and cats<sup>3</sup>. It is one of the fastest sold insecticide across the world because of its high selective toxicity in insects and apparent safety in humans. It acts on nervous system by blocking post synaptic acetylcholine receptors, which kills the insect<sup>4</sup>. Its selective toxicity results from its high affinity to insect's nicotinic acetylcholine receptors compared to mammals<sup>5</sup>. A case of acute poisoning was reported in human following ingestion of a pesticide formulation containing 10% imidacloprid<sup>6</sup> and two fatal intoxication cases have been reported recently<sup>7</sup>. Vitamin C plays an important role in protection against insecticide-induced toxicity as an antioxidant agent and prevents the effect of free radicals on vital cells<sup>8</sup>. Present study was conducted to evaluate the ultra structural alterations induced by imidacloprid in liver, kidney, testis and brain of male rats and protective role of vitamin C against imidacloprid-induced toxicity was also assessed.

## MATERIALS AND METHODS

### CHEMICALS

Imidacloprid was procured from GSP crop science Pvt. Ltd., Gujarat and Vitamin C was obtained from Abbott Health Care Pvt. Ltd., Bhiwandi.

### ANIMALS

Forty eight male *Sprague dawley* rats weighing 200-250 g were procured from National Institute of Nutrition (NIN), Hyderabad. The experiment was conducted as per CPCSEA guidelines and approved by the Institutional Animal Ethics Committee (Approval No. I / 3 / 2012). The rats were housed in solid bottom polypropylene cages at lab animal house in College of Veterinary Science, Hyderabad and were maintained in controlled environment

(Temperature 20-22<sup>0</sup>C) throughout the course of the experiment. Rice husk was used as bedding material. All the rats were provided *ad libitum* with standard pellet diet (procured from NIN) and water throughout the experimental period.

### EXPERIMENTAL DESIGN

Following an acclimatization period of one week, the animals were divided into four groups consisting of 12 in each. Group 1 served as control, group 2 was treated with imidacloprid at the rate of 80 mg/kg b.wt, group 3 was treated with vitamin C at the rate of 10 mg/kg b.wt and group 4 was treated with both imidacloprid and vitamin C. These drugs were administered by oral gavage every day consequently for 28 days. At the end of the experiment all rats were sacrificed by cervical dislocation.

### ULTRA STRUCTURE PATHOLOGICAL EXAMINATION

Soon after sacrifice thin slices of liver, kidney, testes and brain tissues were collected into 2.5% gluteraldehyde in 0.1M phosphate buffer (pH 7.3, stored at 4<sup>0</sup>C), washed in buffer, post fixed in 1% osmium tetroxide in 0.1M phosphate buffer, dehydrated with ascending grades of acetone, embedded in Spurr's resin and were incubated over night at 60<sup>0</sup>C for complete polymerization of the tissue. Semi thin (1000 -1500 nm thickness) sections were made with ultra microtome, stained with 1% toluidine blue to locate exact area to be sectioned for TEM. Then, ultra thin sections were made (500 -700 nm thickness) mounted on hexagonal copper grids, allowed to air dry for overnight and were stained with saturated uranyl acetate and 1% Reynolds's lead citrate as per the protocol of<sup>9</sup>. All grids were dried at room temperature and observed under transmission electron microscope.

## RESULTS AND DISCUSSION


Ultra thin sections of liver in group 2 revealed swollen nuclei, sinusoidal congestion, disrupted chromatin, pleomorphic mitochondria and

disrupted rough endoplasmic reticulum (Fig. 1). Group 4 liver sections showed swollen nuclei (Fig. 2) on day 28. Ultra thin sections of kidney in group 2 revealed degeneration of tubular epithelium, apoptotic nucleus with disrupted and margination of chromatin material, pleomorphic mitochondria and vacuolated cytoplasm (Fig. 3). In group 4, kidney sections revealed inter tubular dilation, apoptotic nuclei and pleomorphic mitochondria (Fig. 4) on day 28. Ultra thin sections of testis in group 2 showed swollen nucleus, increased perinuclear space, varied size and shape of mitochondria and degeneration of spermatids (Fig. 5). Group 4 testis revealed swollen nuclei, margination of chromatin material, altered shape and size of mitochondria (Fig. 6), degeneration of spermatids and apoptotic nucleus (Fig. 7) on 28<sup>th</sup> day of experiment. Ultra thin sections of brain in group 2 revealed apoptotic nuclei with disrupted

and margination of chromatin material (Fig. 8). In group 4, brain section showed degeneration of neurons (Fig. 9) on day 28. These changes might be due to accumulation of imidacloprid metabolites in above organs and also due to the oxidative stress induced by imidacloprid which led to cellular degeneration, dissociation resulted in triggering of apoptosis of damaged cells. Vitamin C plays a primary role in neutralizing free radicals; it can work both inside and outside the cells to combat free radical damage. The free radicals will seek out an electron to regain their stability, vitamin C is an excellent source of electrons so it can donate electrons to free radicals such as hydroxyl and superoxide radicals and quench their reactivity<sup>10</sup>. In the present study, supplementation of vitamin C brought mild protection due to its antioxidant and free radical scavenging effect, resulted in repair and regeneration of damaged tissues.

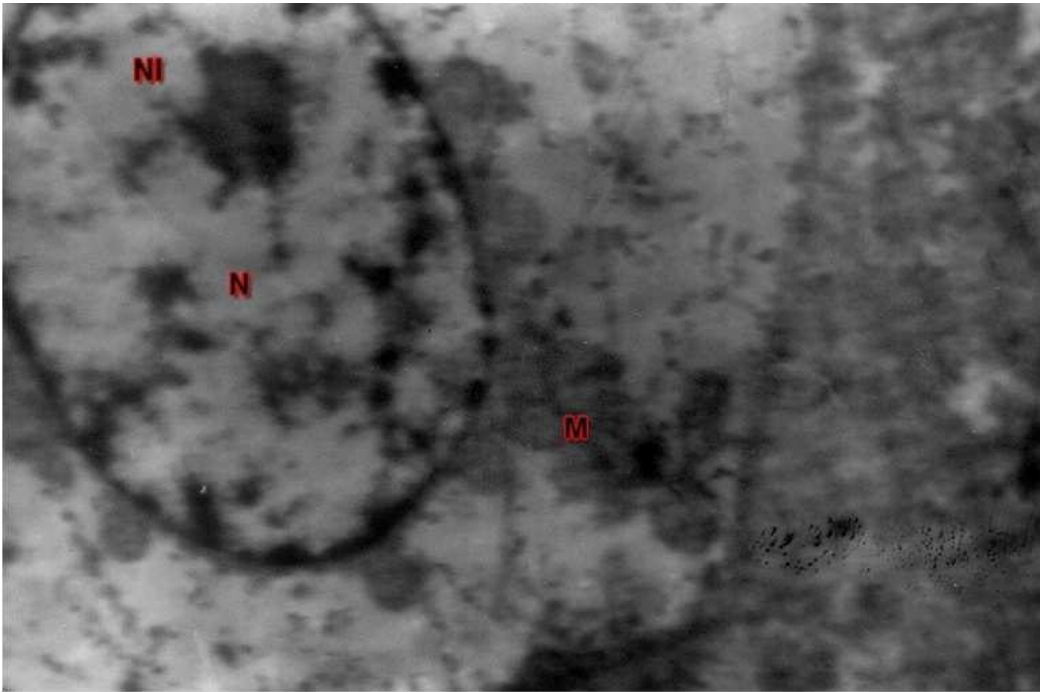
**Figure 1**

***TEM of liver showing swollen nucleus (N), disrupted chromatin (arrow), disrupted endoplasmic reticulum (dER), pleomorphic mitochondria (M) and normal kupffer cell (KC): UA & LC 5580 X (Group 2, day 28)***



**Figure 2**

**TEM of liver showing hepatocyte with swollen nucleus (N), normal nucleolus (NL) and mitochondria (M): UA & LC 7440 X (Group 4, day 28)**



**Figure 3**

**TEM of kidney showing degenerated tubular epithelium with apoptotic nucleus (N), disrupted, margined chromatin material (arrow), pleomorphic mitochondria (M) and vacuolar cytoplasm (VC): UA & LC 4650 X (Group 2, day 28)**






Figure 4

*TEM of kidney showing dilated inter cellular junction (ICjn), tubular epithelial cell with apoptotic nucleus (N), disrupted, marginated chromatin material (arrow) and pleomorphic mitochondria (M): UA & LC 4650 X (Group 4, day 28)*

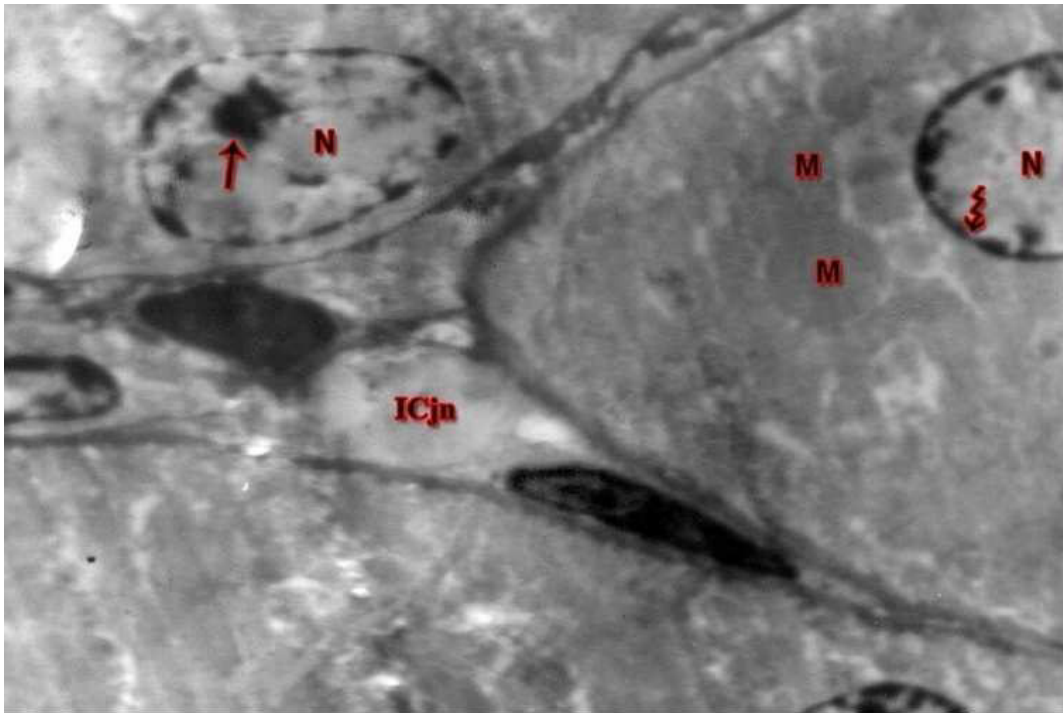


Figure 5

*TEM of testis showing sertoli cell with swollen nucleus (N), increased peri nuclear space (Pns), pleomorphic mitochondria (M), degenerated spermatids (DgSp) and various stages of spermatocytes (SpCyt): UA & LC 9300 X (Group 2, day 28)*

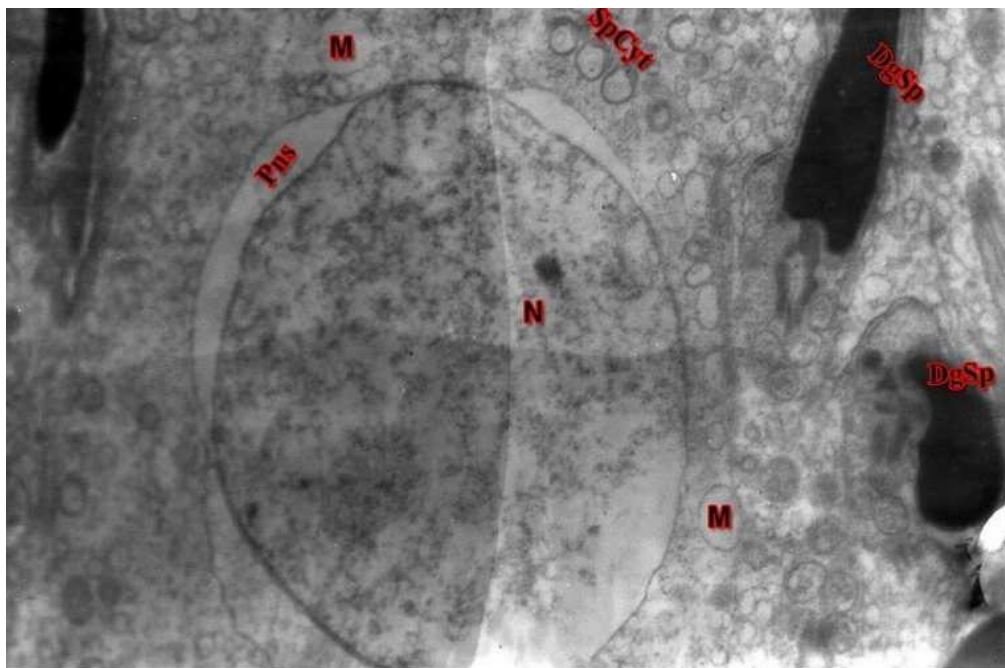


Figure 6

*TEM of testis showing swollen nucleus (N), margination of chromatin material (arrow) and pleomorphic mitochondria (M): UA & LC 4650 X (Group 4, day 28)*

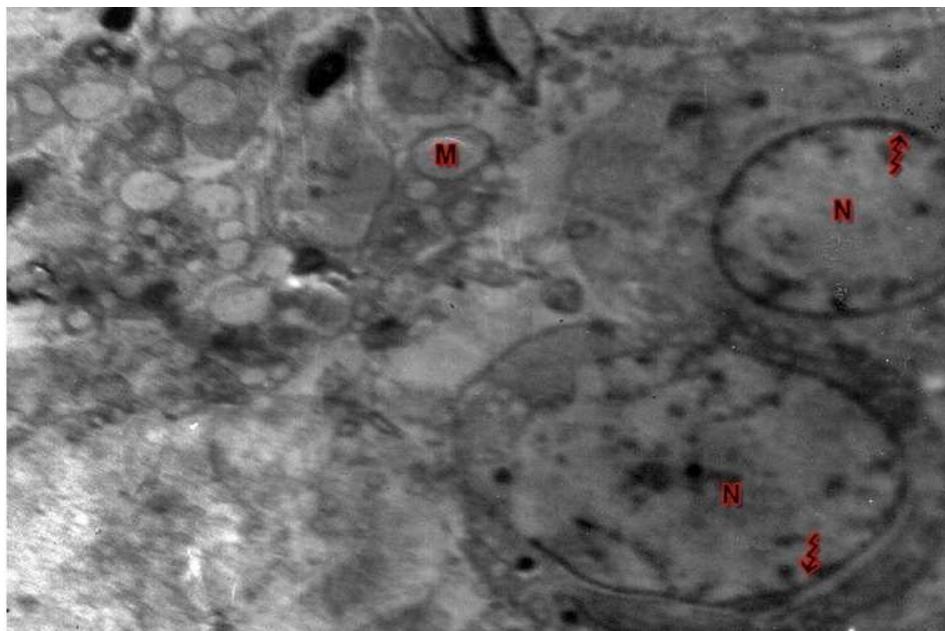
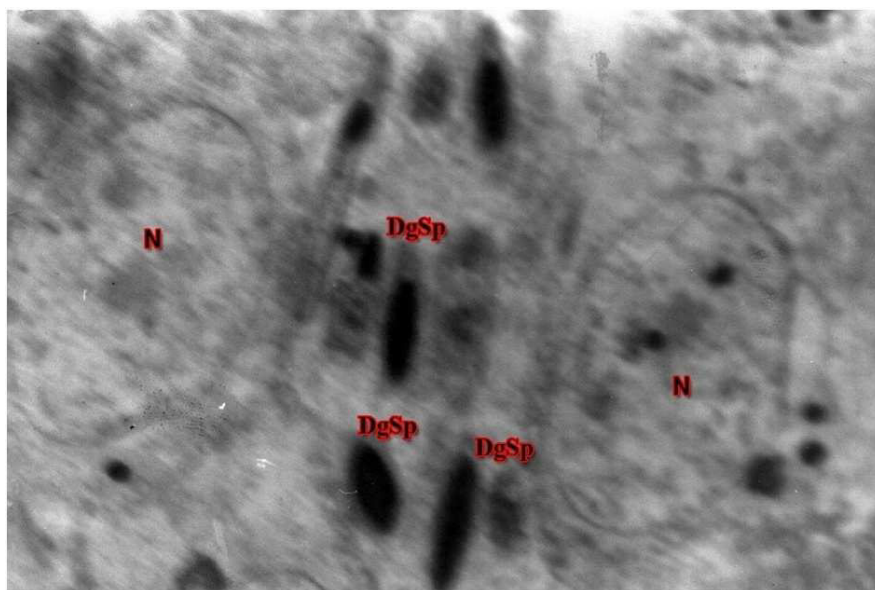
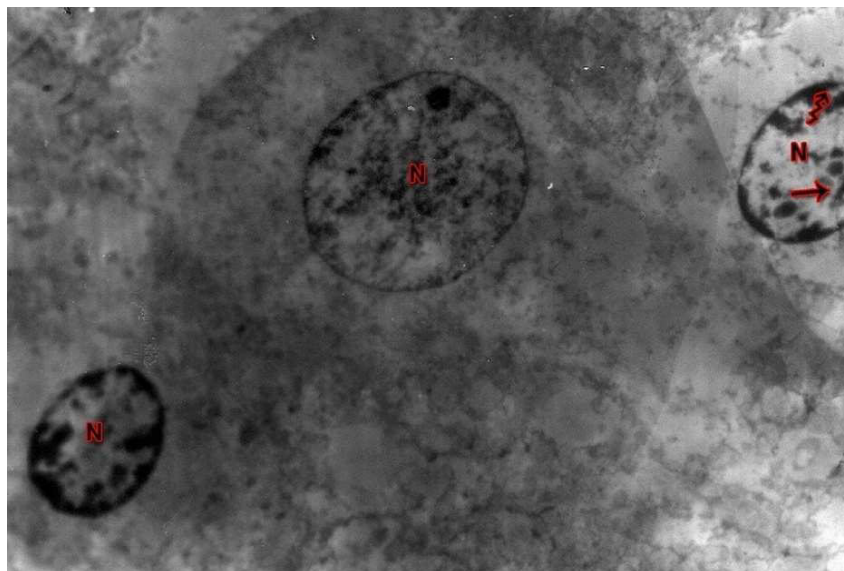


Figure 7

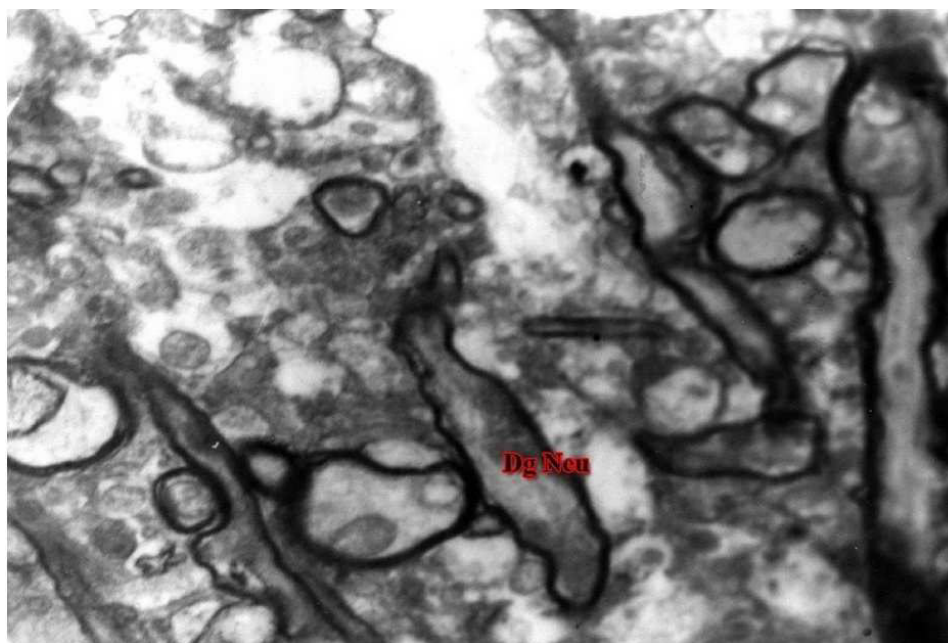
*TEM of testis showing degenerated spermatids (DgSp) and apoptotic nucleus (N): UA & LC 4560 X (Group 4, day 28)*



**Figure 8**  
**TEM of brain showing apoptotic nucleus (N), disrupted and marginated chromatin material (arrow): UA & LC 4650 X (Group 2, day28)**



**Figure 9**  
**TEM of brain showing degenerated neurons (Dg Neu): UA & LC 7440 X (Group 4, day 28)**



## CONCLUSION

The study revealed that exposure to imidacloprid (80 mg/kg) resulted in hepato, nephro, testicular and neuro toxicity in rats, which was evident from ultrastructural alterations in respective organs. However, vitamin C supplementation along with imidacloprid to rats, manifested mild protective effects.

## REFERENCES

1. Cox C. Imidacloprid- Expert overview. Germany. Bayer, (2001)
2. Felsot A. Admiring risk reduction. Agrichemical Environmental News, 186, (2001)
3. Hutchinson M.J., Jacobs D.E. and Mencke N. Establishment of the cat flea (*Ctenocephalides felis*) on the ferret (*Mustela putorius furo*) and its control with imidacloprid. Med. Veterinary Entomology, 15(2): 212-214, (2001).
4. Tomizawa M., Lee D.L. and Casida J.E. Neonicotinoid insecticide toxicology: Mechanisms of selective action. Annuals of Revised Pharmacology & Toxicology, 45: 247–268, (2005).
5. Tomizawa M. and Casida J.E. Selective toxicity of neonicotinoids attributable to specificity of insect and mammalian nicotinic receptors. Annuals of revised entomology, 48: 339-364, (2003).
6. Wu, I-Wen, Lin, a-Liang, Cheng and En-Tsung. Acute poisoning with nicotinoid insecticide imidacloprid in N-methyl pyrrolidone. Clin. Toxicol, 39(6): 617–621, (2001).
7. Proenca P., Teixeira H., Castanheira F., Pinheiro J. and Monsanto P.V. Two fatal intoxication cases with imidacloprid. Forensic Sci. Int., 153: 75–80, (2005).
8. Abd-El-Ghaney A. Study the effect of imidacloprid insecticide on some physiological parameters in Japanese quail. Thesis for M.Sc. Faculty of science, Al-Azhar University, (2002).
9. Bozzala J.J. and Russel L.D. Electron Microscopy Principles Techniques for Biologists. 2<sup>nd</sup> ed. Jones and Barlett Publishers, Sudbury, Massachusetts : 19-45 and 72-144, (1998)
10. Bindhumol V., Chitra K.C. and Mathur P.P. A induces reactive oxygen species generation in the liver of male rats. Toxicology, 188: 117–124, (2003)