Int J Pharm Bio Sci 2013 Oct; 4(4): (P) 255 - 265

Research Article Pharmacology

International Journal of Pharma and Bio Sciences

ISSN 0975-6299

EVALUATION OF ACTIVITY OF WHOLE STEM EXTRACTS OF *OROXYLUM INDICUM* ON PARACETAMOL INDUCED HEPATOTOXICITY.

AMOL NIMBA MORE*[1], PRADEEP B. PARAB[2] AND KISHORI G. APTE[1]

[1]Symbiosis School of Biomedical Sciences (SSBS), Symbiosis International University (SIU), Gram: Lavale; Tal.: Mulshi, Pune- 412 115, India.
[2]APT Research Foundation subsidiary of National Toxicology Centre, S. No. 36/1/1, M. N. 199, Vadgaon Khurd, Pune-411 041.

ABSTRACT

The objective of the present study was to evaluate the activity of the aqueous and ethanolic whole stem extracts of *Oroxylum indicum* in hepatic injury produced with paracetamol.Wistar albino rats were used for the study.Multiple groups were taken for the study each consisting of six rats. Liver injury was induced using paracetamol 2 gm/kg, p.o.as a single dose. The two control groups received oral 1% CMC for 7 days, one of this group received paracetamol on 8th day. The four test groups received aqueous and ethanolic extracts of *Oroxylum indicum* at two different dose levels of 250mg/kg and 500mg/kg (p.o.) respectively for 7 days, followed by the paracetamol administration on day 8, Standard control group received Silymarin as a comparable drug followed by Paracetamol. The serum parameters for liver such as ALT, AST, LDH, ALP, TB and TP were assessed along with the liver antioxidant enzymes LPO, Catalase and GSH. The histopathology analysis of liver was done on 8th day after due sacrificing the rats. Marker enzymes were analyzed in liver tissue. Both the extracts showed significant hepatoprotective activity comparable to that of Silymarin.

KEYWORDS : Paracetamol, *Oroxylum indicum*, Hepatoprotective, Silymarin, ALT, LDH.

AMOL NIMBA MORE
Symbiosis School of Biomedical Sciences (SSBS), Symbiosis International University (SIU), Gram: Lavale; Tal.: Mulshi, Pune- 412 115, India,

INTRODUCTION

Liver is the largest metabolic organ of the body. It performs various functions such as protein synthesis, detoxification and production of biochemicals necessary for digestion. About 29 million people in the European Union have chronic liver disease according to the burden of liver disease in Europe[1]. Xenobiotic, oxidative stress and toxicological effects of chemicals and drugs are mainly responsible for various liver diseases[2]. Paracetamol induced hepatotoxicity is the classic and widely used experimental model to study the hepatoprotective activity of therapeutic drugs[3]. Paracetamol is the metabolite of the phenacetin and widely used as an analgesic and antipyretic drug[4]. The recommended safe adult human dose for paracetamol is about 1.8-2 gms per day. Chronic and prolonged administration of such a dose may cause the liver injury which may lead to liver cirrhosis and mortality[5]. Number of herbal plants and their formulations are used to cure liver disorders since ancient times. The synthetic hepatoprotective drugs are expensive; researchers are now focusing on new herbal drugs which claim to have hepatotoprotective activity[6]. These herbal drugs are also proving their potential in management of various liver disorders[7, 8]. *Oroxylum indicum* belongs to family Bignoniaceae and commonly known as syonaka. The plant possess various medicinal activities such as astringent, diuretic, carminative, stomachic digestive stimulant, aphrodiasic and can alleviate fever and coughs of chronic nature[9]. *Oroxylum indicum* is also the important ingredient of the Ayurvedic formulation Dasamula used in gastrointestinal problems[10]. Root bark, stem bark, leaves, fruits and seeds are traditionally used as medicine because of their major medicinal properties[11]. Therefore, by considering the reported uses of *Oroxylum indicum*, the present study was developed to evaluate the hepatoprotective activity if any, of aqueous and ethanol extracts of whole stem of *Oroxylum indicum.*

MATERIALS AND METHODS

Plant Material

The whole stem of the *Oroxylum Indicum* (OI) was collected from the local medicinal plant suppliers. The whole stem was authenticated from Botanical Survey of India, Pune through voucher no.ORIAPTF1 by Dr. P. G. Diwakar dated 12/07/2011.

Preparation of Plant Extracts

The whole stem of *Oroxylum indicum* (OI) was cleaned, crushed and 40 gm of plant material was kept in the Soxhlet apparatus, the successive extraction was carried out for 24 hours with ethanol first and then with water to obtain ethanolic and aqueous extracts. The aqueous extract (AEOI) as well as ethanol extract (EEOI) obtained were concentrated in rotary evaporator under vacuum and their percent yield was determined. The percent yield obtained were 2.15 % for ethanolic and 2.56% for aqueous extract.

Chemicals

All the chemicals used for this study were of analytical grade. Paracetamol was purchased from Sigma Aldrich Co., Silymarin from Microlabs Ltd., Bangalore and the diagnostic kits used for the Liver Function Test were procured from Pathozyme Diagnostics, Kolhapur.

Animals

The research protocol was approved from the IAEC of National Toxicology Centre, through RP136 dated 16/07/2011.Wistar rats (180-200 gm) of both sexes were procured from in house animal house facility of National Toxicology Centre, Pune. They were housed in standard laboratory condition with 12 hrs light/dark cycle. Animals were fed a standard laboratory diet with water *ad libitum*.

Acute toxicity study

The acute oral toxicity of both plant extracts were carried out using, female swiss albino mice of 18-22 gm of body weight. The study was performed according to the OECD Guidelines, 423[12]. The animals were dosed orally once 2000 mg/kg of the both aqueous and ethanol extracts respectively. The animals were observed for 14 days for any mortality or other signs of acute toxicity.

Animal Experimentation

Albino wistar rats of either sex were taken in following groups

Group I

Normal Control received 1% Carboxy Methyl Cellulose (CMC) suspension p.o. for 7 days.

Group II

Disease Control, received 1% Carboxy Methyl Cellulose (CMC) suspension p.o. for 7 days followed by Paracetamol 2 gm/kg p.o. on day 8.

Group III

Standard Control received Silymarin 100mg/kg p.o. for 7 days followed by Paracetamol 2 gm/kg p.o. on day 8.

Group IV

Test 1 received AEOI 250 mg/kg p.o. for 7 days followed by Paracetamol 2 gm/kg p.o. on day 8.

Group V

Test 2 received AEOI 500 mg/kg p.o. for 7 days followed by Paracetamol 2 gm/kg p.o. on day 8

Group VI

Test 3 received EEOI 250 mg/kg p.o. for 7 days followed by Paracetamol 2 gm/kg p.o. on day 8.

Group VII

Test 4 received EEOI 500 mg/kg p.o. for 7 days followed by Paracetamol 2 gm/kg p.o. on day 8.

After 24 hrs of the last treatment with paracetamol all the animals were anaesthetized with ketamine and xylazine, blood was collected through heart puncture, was allowed to clot for 1 hr followed by centrifugation at 3000 rpm for 15 minutes and the serum was separated, collected and analyzed for different biochemical parameters. Liver from all the animals were dissected weighed. Half of the liver was preserved in formalin for histopathology study and half was used to determine an antioxidant enzymes.

Liver Function Tests

Biochemical Test

Biochemical parameters such as ALT, AST, Lactate Dehydrogenase (LDH), Alkaline Phosphatase (ALP), Total Bilirubin (TB) and Total Protein (TP) were performed using standard Biochemical kits as mentioned above.

Liver antioxidant Enzymes

Lipid Peroxidase (LPO)[13], Catalase [CAT; EC: 1.11.1.6][14] and Reduced Glutathione (GSH) [15] were analysed from 10% liver homogenates. A 10% liver homogenate was prepared using 1X PBS. The homogenate was then centrifuged and the supernatant was used for the estimation of the above mentioned enzymes.

Histopathological observation

The portion of the liver was transferred to 10% formalin solution allowed to fix and then the histopathology study was performed for observing any histological changes after paracetamol administration.

Statistical analysis

The results are expressed as Mean± SD, statistical analysis was done by One way ANOVA using Graph Pad Prism, Version 5 (Dunnett's Multiple comparison tests.) at 99% Confidence Limit.

RESULTS

Acute Toxicity Study

At the end of 14 days none of the animal showed sign and symptoms of mortality, which suggested that the dose of 2000 mg/kg extracts were safe. Considering wide margin of safety of both extracts as observed in acute toxicity, 250 mg/kg and 500 mg/kg doses were selected for the present study.

Liver Function Test

Effects of OI on ALT levels

There was a significant increase ($p<0.01$) in the serum enzyme level of ALT in the Disease control group when compared with Normal

Control group. The Silymarin and both aqueous and ethanol extracts treated groups of OI showed significant decrease in the levels of ALT when compared with disease control group (Figure 1).

Figure 1
Effect of different extracts of Oroxylum indicum and standard drug on ALT level.

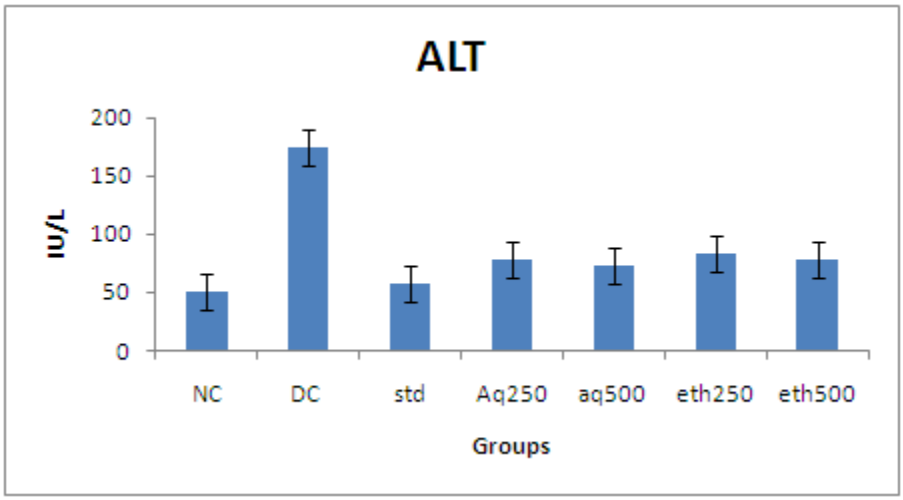

Effect of extracts of OI on LDH level

The LDH levels showed significant increase ($p<0.01$) in Disease Control group as compared with Normal Control group at the end of study. Both the extract treated groups of OI and standard drug treated group showed marked reduction in LDH levels when compared with Disease Control group (Figure 2).

Figure 2
Effect of different extracts of Oroxylum indicum and standard drug on LDH level.

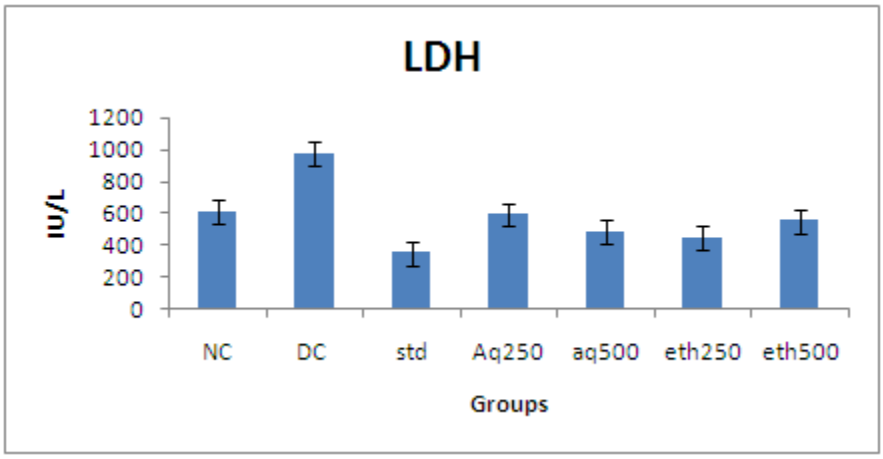

Effect of extracts of OI on AST, ALP and TB level

Both the extracts of *Oroxylum Indicum* showed marked reduction in enzyme levels of AST, ALP and TB when compared with Disease Control group (Table 1).

Effect of extracts of OI on TP

There was a significant decrease in Total Protein levels in Disease Control group as compared to test drug treated and standard drug Silymarin treated groups (Table 1).

Table 1
Effect of extracts of OI on Liver Biochemical Parameteres

Group	AST (IU/L)	ALP (U/L)	TB (mg/dl)	TP (gm/dl)
NC	238.51±15.05	284.33±10.09	4.32±0.19	8.00±0.14
DC	402.73±20.62###	503.83±10.04###	9.97±0.77###	4.56±0.49###
Std	212.91±20.11***	297.00±9.35***	4.83±0.46***	8.96±0.44***
AEOI 250mg/kg	243.14±18.92***	372.16±4.79***	6.33±0.30***	7.76±0.25***
AEOI 500 mg/kg	225.45±11.41***	387.83±8.54***	6.73±0.71***	8.58±0.27***
EEOI 250 mg/kg	227.54±17.51***	391.16±8.20***	6.72±0.41***	6.98±0.11***
EEOI 500 mg/kg	208.07±15.60***	337.50±9.26***	6.45±0.25***	7.63±0.38***

Data: n=6, All Values are expressed as Mean ± SD.
****** P < 0.01 when compared with disease control; ### P < 0.01 when compared with normal control***

Effect of extracts of OI on tissue antioxidant enzymes
Effect on LPO levels

There was a significant increase in Tissue LPO levels in the paracetamol induced liver injury in disease control group as compared to normal control group. Pretreatment with both the extracts of OI showed a reduction in tissue LPO levels as compared to disease control group.However, the standard control group showed significant decrease in the LPO levels as compared to disease control group also. (Table 2)

Effect of extracts of OI on Catalase

The groups treated with OI extracts and Silymarin showed significant increase ($p<0.01$) in Catalase level as compared with the disease control group (Table 2).

Effect of extracts of OI on Reduced Glutathione

In the GSH level, aqueous extract of OI at 500 mg/kg showed significant increased as compared to disease control group. While other extract treated groups and Silymarin treated groups showed moderate increase in GSH levels (Table 2).

Table 2
Effect of Oroxylum indicum on tissue antioxidant enzymes.

Group	LPO (moles/gm)	Catalase (U/gm)	GSH (mg/gm)
NC	4.95±0.63	42.02±9.82	1.72±0.28
DC	7.38±0.46###	26.92±3.62###	0.96±0.15###
Std	2.43±0.18***	63.46±11.99***	1.54±0.26***
AEOI 250MG/KG	6.04±1.99ns	43.94±6.53**	1.42±0.29**
AEOI 500MG/KG	5.23±1.28*	56.76±2.55***	1.25±0.18***
EEOI 250MG/KG	4.69±1.13**	58.33±7.11***	1.47±0.36ns
EEOI 500MG/KG	3.99±1.69***	42.66±8.17**	1.32±0.13**

Data: n=6, All Values are expressed as Mean ± SD.
****** P < 0.01 when compared with disease control; ### P < 0.01 when compared with normal control, ns= non significant***

Histopathology of Liver Tissue

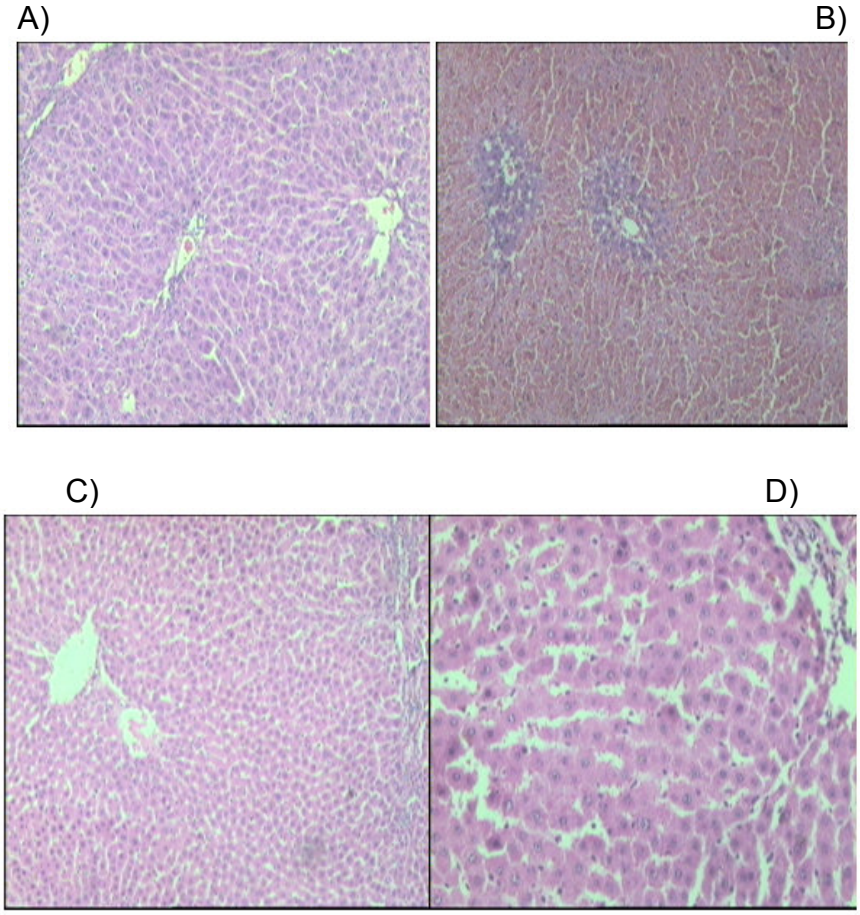

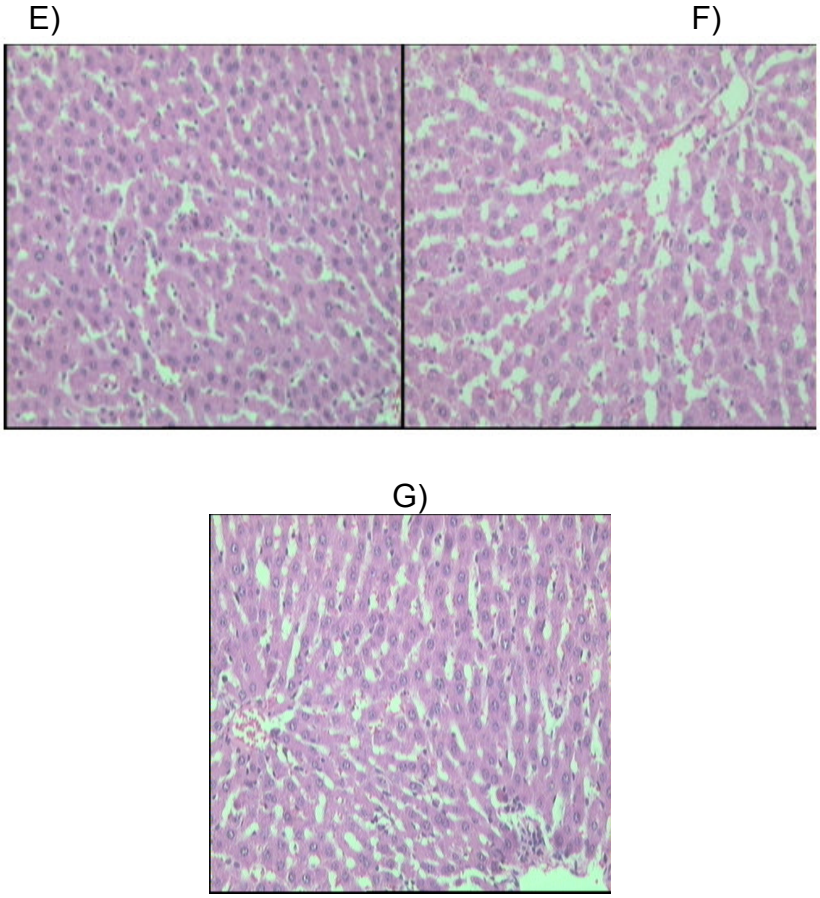

Figure 1
Histology photos of the liver in rats A) Normal Control B) Paracetamol Treated C)Standard (Silymarin) treated, D)Aqueous extract of OI at 250mg/kg, E) Aqueous extract of OI at 500mg/kg, F) Ethanolic extract of OI at 250mg/kg, G) Ethanolic extract of OI at 500mg/kg, stained with Hematoxylin and Eosin.

The histopathology of the normal control group showed normal histoarchitecture (A). The group treated with the paracetamol showed wide areas of haemorrhagic necrosis (B), whereas the group treated with standard drug showed sinusoidal dilation with few RBC's (C). The treatment with aqueous extract of *Oroxylum indicum* at a dose of 250 mg/kg and 500 mg/kg showed almost normal histoarchitecture with some dilatation and few RBC's (D,E). The animals treated with ethanol extract of *Oroxylum indicum* showed sinusoidal dilatation with few RBC's (F, G).

DISCUSSION

Liver disorders are serious health problems in modern era, and is challenge to the modern therapeutics[16] as around 20,000 deaths are reported in the world every year due to liver disorders[17]. Paracetamol is widely used as an antipyretic and analgesic drug which can produce hepatic necrosis at high doses. Generally, it is eliminated from the body as sulfate and glucuronide. At high doses paracetamol molecules are oxidized to highly reactive NAPQI by cytochrome-450 enzymes. Reduction of NAPQI results in semiquinone radicals which bind to macromolecules of cellular membrane which results in increase in the lipid peroxidation resulting in tissue damage. Depletion in the liver GSH concentration is due to high dose of paracetamol and NAPQI which produces the alkylate which oxidizes the intracellular GSH[18-24]. Membrane damage or necrosis to liver cells can release enzymes such as ALT, AST, LDH,

ALP, TP into circulation which can be measured in the serum. ALT is more specific to liver and a better parameter to evaluate the hepatic injury because AST levels also increases in viral hepatitis, cardiac infarction and muscle injury and liver damage. Elevated levels of serum enzymes are the indication of loss of functional integrity of cell membrane and cellular leakage in liver[25]. In the present study paracetamol significantly elevated the levels of ALT, AST, ALP, LDH, TB, LPO and decreased levels of TP, Catalase and GSH ($p<0.01$). After administration of the plant extract and silymarin the levels of these enzymes restored to almost normal level. In this study it has been observed that the paracetamol intoxication lead to the elevated levels of ALT in the disease control group. The groups treated with aqueous extract of OI at a dose of 500mg/kg showed approximately 57% reduction in elevated ALT levels. However the maximum reduction rate after treatment with Silymarin was 66.26%. The ethanol extract at 500 mg/kg dose showed 55.98% reduction in elevated ALT level. Lactate dehydrogenase, a glucose metabolizing enzyme is a potent marker of xenobiotic injury[26]. In the present study there was significant increase in the serum enzyme levels of LDH in disease control group ($p<0.01$) as compared with normal control group and the groups treated with Silymarin and different extracts of the OI significantly decreased the LDH level. The formation of altered proteins decreases the normal protein production in liver which is an indication of the liver cell injury[27]. In the present study, it has been observed that there was a significant decrease in the serum total protein levels in disease control group as compared to normal control group, whereas, the groups treated with standard drug increased the protein level by 49.10 % and different extracts of OI increased the protein levels by 46.85% respectively. AST, ALP and Total Bilirubin are the enzymes present in higher concentrations in cytoplasm. Whenever liver injury occurs these enzymes gets leaked into the blood stream and serum levels get elevated[28]. In the present study there was a marked increase in the enzyme levels of AST, ALP and TB in the disease control group while in case of the standard and extract treated groups there was significant reduction was observed in the levels of the above mentioned enzymes. Glutathione plays an important role in the maintenance of various proteins and lipids for cellular functions. GSH can be reduced by toxic effects of the oxidative stress which results in cellular damage. In this study it was observed that the group treated with paracetamol (Disease control) lowered the GSH level while groups pretreated with Silymarin and extracts of the OI showed increase in the GSH levels which may be because of the antioxidant effect of the plant extracts[29]. Increased level of LPO is the result of the membrane damage. In our study, Group treated with Paracetamol alone (Disease control) showed an elevated levels of LPO, which was found to be reduced by OI extracts treated groups which was also comparable with Silymarin[30]. Catalase protects the tissue from highly reactive hydroxyl radicals by decomposing the hydrogen peroxide. So, reduced levels of catalase may indicate the toxic effects on the tissue. A higher dose of ethanolic extract of OI showed 53.84% increased ($p<0.01$) levels of catalase when compared with the Disease control group, which can be a free radical scavenging activity of the plant extract. Also, the standard drug treated and other groups treated with the different extracts of OI showed significant ($p<0.01$) increase in Catalase level[31]. In the histopathology, the entire centrilobular and hepatic vein architecture of the liver is replaced by extensive areas of haemorrhages and necrosis, No viable hepatocytes are seen in this areas for the group treated with paracetamol. While, the groups treated with extracts and standard showed the thrivial changes only and the extent of haemorrhages are restricted to small parenchyma while other areas are spared, which is a clear indication of hepatoprotective activity of the plant material.

Efficacy of the hepatoprotective drug can be given on its capacity to reduce the harmful effect or by restoring the normal hepatic cellular physiology distributed by a hepatotoxin. The

standard drug and plant extract showed the protection of structural integrity of hepatocytic cell membrane or regeneration of damaged liver cells which is proven by decreased elevated levels of enzymes. Both the extract showed significant protective effects with respect to biochemical and histological parameters of hepatic injury. It is reported that the OI contains the alkaloids, flavonoids and phenolic compounds which may be responsible for this hepatoprotective activity[32].

CONCLUSION

The present studies indicated that the aqueous and ethanolic extracts of *Oroxylum indicum* prevents hepatic damage caused by paracetamol in rats either by neutralizing the oxidative stress or by reducing toxic metabolite (NAPQI). The hepatoprotective activity may be due to antioxidant fractions present in the plant extracts. Further study is needed to identify and isolate the active principles from OI which are responsible for antioxidant and hepatoprotective properties. Further studies are required to prove its potential use as a hepatoprotective drug in clinical practice.

ACKNOWLEDGMENT

The authors are thankful to Dr. Avinash Pradhan (M.D. Pathology) for providing histopathological observations. The authors are also, very thankful to all the staff of National Toxicology Centre and APT Research Foundation for their encouragement and providing facilities to carry out this work.

REFERENCES

1. Liver disease in Urope, The Lancet, Volume 381, Issue 9866, Page 508, 16 February 2013
2. Wolf P, Biochemical diagnosis of liver diseases. Indian J Clin Biochem, 14: 59–90, (1999)
3. Franchesca M, Gutierrez M, Leano R, Solidum N, Evaluation of the hepatoprotective activity of *Citrus microcarpa* Bunge (Family Rutaceae) fruit peel against acetaminophen-induced liver damage in male BFAD- Sprague Dawley rats. Int J Chem Environ Engin 1(2): 127-132, 2010.
4. Roberts L.J., Marrow J.D., Hardman J.G. and Limbird L.E., Analgesic-antipyretic and anti-inflammatory agents and drugs employed in the treatment of Gout in “Goodman and Gilman’s” the Pharmacological basis of therapeutics. Phar. Ther., 10th Edn, 687-731, (2001).
5. Rumack H, Peterson R, Koch G and Amara I, Acute acetaminophen overdose. Intern med., 14: 380-385, 1981.
6. Emeigh H, Wyand D, Khairallah E and Cohen S, Acetaminophen nephrotoxicity. Tox. Ap. Phar., 136: 161-169, 1996.
7. Hemamalini K, Preethi B, Bhargav A, Vasireddy U, Hepatoprotective activity of *Kigelia africana* and *Anogeissus accuminata* against paracetamol induced hepatotoxicity in rats. *Int J Pharm Biomed Res, 3*(3): 152-156, 2012.
8. Girish C, Koner C, Jayanthi S, Ramachandra K, Rajesh B, *et al.,* Hepatoprotective activity of picroliv, curcumin and ellagic acid compared to silymarin on paracetamol induced liver toxicityin mice., Fundam Clin Pharmacol, 23(6): 735-745, (2009).
9. Malar L, Mary S, Mettilda B, Hepato-protective activity of *Phyllanthus emblica* against paracetamol induced hepatic damage in wistar albino rats. African J Basic & Applied Sci, 1(1-2): 21-25, (2009).
10. The Herbal Pharmacopoeia Of India, Regional Research Laboratory, Jammu And Indian Drug Manufacturers Association, Mumbai, 165, (1998).

11. Zaveri M, Jain S, Phytopharmacognostical studies on root bark of O*roxylum indicum*, Vent., International Journal of Pharmaceutical Sciences Review and Research, 4(1); 132-135, (2010).
12. Goswami V, Sharma S, Modi A, Telrandhe B and Patil J, Effect of Various Extracts of *Tectona grandis* Linn. Bark on Bronchitis. Pharmacologyonline, 1: 816-820, (2010).
13. Ohkawa H, Ohishi M, Yagi K, Assay of lipid peroxides in animal tissues by thiobarbituric acid reaction. Anal Biochem 95: 351-358, (1979).
14. Aebi H, Catalase *in vitro*. Methods in Enzymol 105: 121-126, (1984).
15. Moron S, Depierre W, Mannervik B, Levels of glutathione, glutathione reductase and glutathione S-transferase activities in rat lung and liver. Biochim Biophys Acta, 582: 67-78, (1979).
16. Vidhya Malar H and Mary Mettilda S, Hepato-Protective Activity of *Phyllanthus emblic*a Against Paracetamol Induced Hepatic Damage in Wister Albino Rats, African Journal of Basic & Applied Sciences, 1 (1-2): 21-25, (2009).
17. Sharma B, Sharma K, Hepatoprotective activity of some indigenous plants. Int J PharmTech Res, 2(1): 568-572, (2010)
18. Jain M, Kapadia R, Jadeja RN, Thounaojam MC, Devkar RV, Mishra SH. Cytotoxicity evaluation and hepatoprotective potential of bioassay guided fractions from Feronia limmonia Linn leaf. Asian Pac J Trop Biomed 2011; 1(6): 443-447.
19. Ravikumar S, Gnanadesigan M. Hepatoprotective and antioxidant activity of a mangrove plant Lumnitzera racemosa. Asian Pac J Trop Biomed 2011; 1(5): 348-352.
20. Sengupta M, Sharma GD, Chakraborty B. Hepatoprotective and immunomodulatory properties of aqueous extract of Curcuma longa in carbon tetra chloride intoxicated Swiss albino mice. Asian Pac J Trop Biomed 2011; 1(3): 193-199.
21. Devaraj VC, Krishna BG, Viswanatha GL, Kamath JV, Kumar S. Hepatoprotective activity of Hepax-A polyherbal formulation. Asian Pac J Trop Biomed 2011; 1(2): 142-146.
22. Erukainure OL, Ajiboye JA, Adejobi RO, Okafor OY, Adenekan SO. Protective effect of pineapple (Ananas cosmosus) peel extract on alcohol-induced oxidative stress in brain tissues of male albino rats. Asian Pac J Trop Dis 2011; 1(1): 5-9.
23. . Thirumalai, Therasa SV, Elumalai EK, David E. Intense and exhaustive exercise induce oxidative stress in skeletal muscle. Asian Pac J Trop Dis 2011; 1(1): 63-66.
24. Wilma DSC, Kavya N, Kulkarni S. Evaluation of insulin sensitivity status in polycystic ovarian syndrome. Asian Pac J Trop Dis 2011; 1(1): 67-70.
25. Rajkapoor B, Venugopal Y, Anbu J, Harikrishnan N, Gobinath M, Ravichandran V. Protective effect of Phyllanthus polyphyllus on acetaminophen induced hepatotoxicity in rats. Pak J Pharm Sci 2008; 21(1): 57-62.
26. Kaur A, Binepal G and Gangar S, ”Impediment of diethylnitrosamine induced hepatotoxicity in male Balb/c mice by pretreatment with aqueous *Azachirachta indica* leaf extract”, Indian Journal of Experimental Biology, 45: 359-366, (2007).
27. Ekam S, Johnson T, Dasofunjo K, Odey O and Anyahara E, Total protein, albumin and globulin levels following the administration of activity directed fractions of *Vernonia amygdalina* during acetaminophen induced hepatotoxicity in wistar rats, Annals of Biological Research, 3 (12): 5590-5594, (2012)
28. Anantha Krishna Chaitanya D, Siva reddy Challa, Manohar Reddy A.”Hepatoprotective effect of biherbal ethanolic extract against paracetamol induced hepatic damage in albino rats”, Journal of Ayurveda and integrative Medicine, 3(4), 198-203, (2012).
29. Fraga G, & Oteiza I, Iron toxicity and antioxidant nutrients, Toxicology, 80: 23, (2002).
30. Desai S, Gite M, Ahmad A, More Y, Gavitre B, Gawali V, Hepatoprotective and Antioxidant Activity Evaluation of PHF08 on

Carbon Tetrachloride Induced Hepatotoxicity, Scholars Research Library, 2 (1): 475-481, (2010).

31. Rajkapoor B, Venugopal Y, Anbu J, Harikrishnan N, Gobinath M and Ravichandran V, protective effect of *phyllanthus polyphyllus* on acetaminophen induced hepatotoxicity in rats, Pak. J. Pharm. Sci., 21(1): 57-62, (2008).
32. Tripathy B, Panda S, Sahoo S, Mishra K, Nayak L, Phytochemical Analysis and Hepatoprotective Effect of Stem Bark of *Oroxylum indicum* (L) Vent. On Carbon Tetrachloride Induced Hepatotoxicity in Rat, International Journal of Pharmaceutical & Biological Archives 2(6):1714-1717, (2011).