



## A STUDY OF MANAGEMENT OF SUPRACONDYLAR FRACTURES OF HUMERUS IN CHILDREN BY CLOSED REDUCTION AND PERCUTANEUS PINNING

**DR.K BRAHMESWARA RAO<sup>1</sup> AND DR.AMARVISHAL\*<sup>2</sup>**

*<sup>1</sup>ORTHO RESIDENT ASRAM Medical College, ELURU. Andhra Pradesh.*

*<sup>2</sup>PROFESSOR OF ORTHOPAEDICS ASRAM Medical College, ELURU. Andhra Pradesh.*

### ABSTRACT

Supracondylar fractures of humerus is one of the few fractures which when treated well may not bring credit to a reputed surgeon but if not handled properly, it can definitely bring discredit to a well reputed surgeon. Fractures around the elbow often lead to considerable pain, deformity and permanent restriction of motion limiting the use of hand in most activities. Positioning of hand for grip and prehension is dominated by freedom of motion at the elbow. Any restricted motion of the neck, shoulder or wrist magnifies impairment of elbow. In this study 50 children who had sustained supracondylar fractures Gartland type 2 (10 cases) & type 3 (40 cases) were treated in the department of orthopaedics Asram Hospital, Eluru. Children within the age group of 4-13 years were included in our study. In our study of 50 cases, the outcome of 18 cases was excellent, 20 cases was good, 8 cases was fair and in 4 cases poor results were observed. Displaced supracondylar fracture humerus can be better managed with closed reduction and percutaneous pin fixation than with closed manipulation alone. Percutaneous k-wire fixation is a safe and effective method for the management of Gartland type 2 & type 3 supracondylar fractures with minimal hospital stay. Percutaneous k-wire fixation provides good fracture stability, good union & acceptable complication rate with minimal risk of iatrogenic nerve injuries.

**KEY WORDS: CHILDREN DISPLACED SUPRACONDYLAR FRACTURES CLOSED PINNING**



**DR.AMARVISHAL**

**PROFESSOR OF ORTHOPAEDICS ASRAM Medical College, ELURU. Andhra Pradesh.**

## INTRODUCTION

Fractures around the elbow lead to considerable pain and sometimes permanent restriction of motion limiting the use of hand in most activities. Basic daily activities from eating to perineal hygiene require a wide range of positions and movements at the elbow in both flexion and extension and forearm rotations. More complex tasks at work place or in recreation require even greater functional demands.

## MATERIALS AND METHODS

The present study involved 50 children who had sustained supracondylar fractures Gartland type 2 (10 cases) & type 3 (40 cases), who were treated in the department of orthopaedics ASRAM Hospital, Eluru. Children within the age group of 4-13 years were included in our study. Average period from injury to presentation was 8 hours, mean age being 8 years. Out of 50 cases 32 were boys and 18 were girls. 19 patients presented with involvement of right side and 31 of the left side. Average period from injury to surgery was 12 to 20 hours

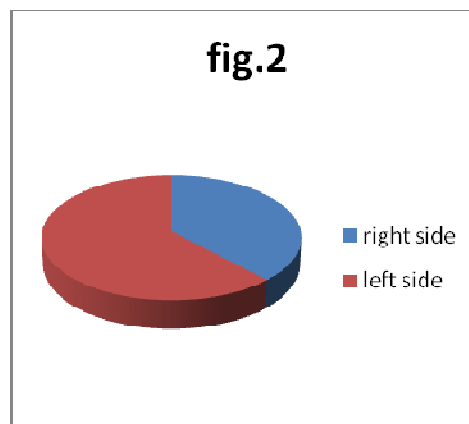
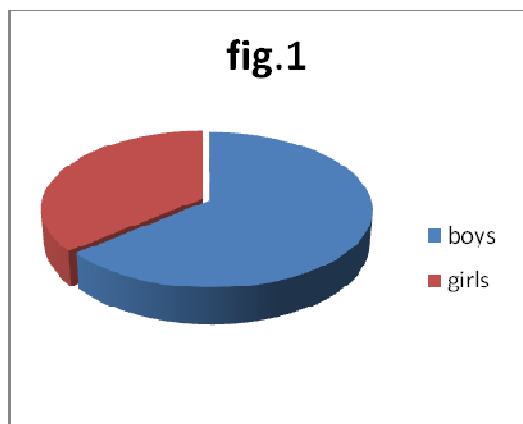
All cases were treated with closed manipulation & per-cutaneous k-wire fixation under c-arm control and immobilized in above elbow pop back slab. Most of the cases were treated with closed reduction and fixation with one lateral and one medial k wire through the respective epicondyles. Few cases with considerable oedema were treated with 2 parallel lateral k wires to avoid risk of injury to ulnar nerve. After 3 weeks of immobilisation active range of motion was started. All the k wires were removed by 4 weeks. The children were followed up for a period of 12 months and range of motion and carrying angles were noted at regular intervals of 3 weeks, 6 weeks, 6 months, and 12 months..

### INCLUSION CRITERIA

Children coming to our hospital within the age group of 4-13 years are included in our study.

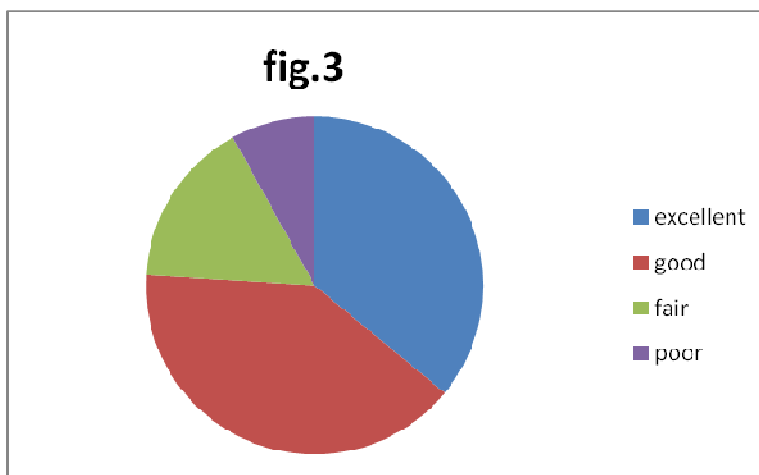
### EXCLUSION CRITERIA

More than 5 days from injury.  
Any supracondylar fractures extending to the intercondylar part of the humerus.



## RESULTS

In our series, 50 cases of closed reduction under c-arm with percutaneous fixation were done. 12 cases were stabilised using 2 parallel k-wires through the lateral epicondyle of humerus, and 38 cases were stabilised with k-wires applied from medial and lateral epicondyles. Out of 50 cases, 18 cases had excellent, 20 cases had good, 8 cases had fair and 4 cases had poor results. (satisfactory results 92%) Fig.3, based on Flynn et al grading



It was observed that closed reduction & percutaneous k-wire fixation is better, rather than attempting more number of manipulations and accepting inaccurate reduction. The most important complication noted in supracondylar fracture humerus is cubitus varus deformity, due to medial rotation of distal fragment. It can be effectively managed with french osteotomy.

## DISCUSSION

Percutaneous k-wire fixation is a safe and effective method for the management of Gartland type 2& type 3 supracondylar fractures. There is no risk of losing the reduction if wires are placed properly. The complications like superficial pin tract infection and ulnar nerve irritation are negligible. Early joint mobilisation is possible and the incidence of mal-union is considerably lower when care is taken in anatomically reducing the fracture

## REFERENCES

1. Blount p: fractures in children. Baltimore. Williams 8s wilkins,28,1955
2. Rang' 11:childrens fracture. Philadelphia : JB Lippincott.98.19i-1
3. BosanquetJS.MiddletonRW:the reduction of supracondylar fractures of humerus in children treated by traction in extension. Injury, 14:373, 1983"
4. Dodge HS ; Displaced supracondylar fractures of humerus in children:treatment by Dunlops traction. J Bone joint surg(AM),54:1408,1972
5. Dunlop J : transcondylar fractures of the humerus in childhood.J Bone joint surg(AM),21:59,1939
6. Smith L; Deformity following supracondylar fracturesofthhumerus. J BONE JOINT SURG(AM), 42:235, 1960
7. Aronson DD, PragerB1: supracondylar fractures in children,ClinOrthops, 219: 174, 1987.
8. Boyd DW, Aronson DD : supracondylar fractures of the humerus: A prospective study of percutaneous pinning. JPediatrORthop, 12:789, 1992

and proper technique is followed in placement of the wires. In our study Percentage of cases with varus residual were 6% and percentage of cases with valgus residual were 2%.

## CONCLUSION

- Supracondylar fracture humerus is more common in children in 5-8 years age group.
- It has male preponderance
- It is more common on the left side.
- Most of the cases are Gartland type 3 with postero medial displacement.
- Displaced supracondylar fracture humerus can be better managed with closed reduction & percutaneous pin fixation than closed manipulation alone.