



AN UNUSUAL FOREIGN BODY IN ADULT LARNYX

DEEKSHITH R M¹ AND SHRIKRISHNA B H²

¹ Senior resident, Department of Otorhinolaryngology-Head & Neck Surgery,
Kurunji Venkataramana Gowda Medical College, Kurunjibag, Sullia-574327 D K .

² Associate Professor, Department of Otorhinolaryngology-Head & Neck Surgery, Navodaya Medical
College Mantralayam Road, Raichur-584103. email id: drshrikrishna@gmail.com

ABSTRACT

Foreign body aspiration can result in a spectrum of presentations, from minimal symptoms, often unobserved, to respiratory compromise, failure, and even death. Foreign body larynx is not a common occurrence. Prompt diagnosis and removal of the foreign body is often life saving. We present an unusual case of foreign body larynx, where a 60 year old lady accidentally inhaled a weed seed and developed sudden onset of respiratory distress and change in quality of voice. Emergency tracheostomy was done to establish the airway following which the foreign body was removed by microlaryngoscopy.

KEY WORDS: foreign body, larynx, tracheostomy, voice, glottis.



DEEKSHITH RM

Senior resident, Department of Otorhinolaryngology-Head & Neck Surgery,
Kurunji Venkataramana Gowda Medical College, Kurunjibag, Sullia-574327 D K .

INTRODUCTION

The space between the vocal cords is 'rima glottidis' and mucosa covering them is glottis¹. Glottis is the area of opening to lower respiratory passages. It is the narrowest part of cavity of larynx². Impaction of foreign bodies in larynx is more likely to occur in children than in adults. Even though it is not unusual to find a foreign-body impacted in the larynx in an adult patient, it is almost impossible to see a patient who presents 2 days after aspiration of a foreign body with difficulty in breathing and change in quality of voice.

CASE REPORT

A 60 year old female came to our Out Patient Department with a history of stridor and pain in the throat and weak voice. She is a shepherd by occupation. She was grazing her goats in the field and slept under a tree to take rest in the afternoon. The seeds of the tree were falling on her saree due to the wind. She had an accidental inhalation of a seed while she tried to cover her face with her saree while sleeping. This was followed by violent coughing, sudden change in her voice and pain in the throat. She started feeling difficulty in breathing. She consulted a local doctor at her village who referred her to an ENT surgeon. She tolerated the symptoms for 2 days as she was all alone at home and came to our OPD with her daughter who had come to meet her. On examination, she was alert, conscious and co-operative. There was no cyanosis. Mild stridor was present and voice was hoarse. Examination of the larynx using a 70⁰ Hopkins telescope in the OPD revealed the presence of a black thorny seed in the glottis lodged in an antero posterior direction with oedema of the vocal folds. She was

admitted immediately and patient was explained about the need for an emergency tracheostomy prior to any attempt of removal of foreign body. After taking written and informed consent, direct laryngoscopy was done to confirm the presence of foreign body in the larynx. Emergency tracheostomy was done under local anesthesia and the airway was secured. Tracheal intubation was done through the tracheostome and general anesthesia administered (Fig 1). Microlaryngoscopy was done with 400 mm objective lens and chest fixation. A thorny black seed was seen to impact between the true vocal cords (Fig 2). The foreign body was removed using a foreign body grasping forceps. The foreign body was having thorny projections (Fig 3), measuring around 1cm in diameter (Fig 4). On careful inspection, one of the thorns of the seed was found to be still impregnated in the right true vocal cord and was removed carefully. The bilateral true vocal cords were lacerated by the thorns (Fig 5). Endotracheal tube was extubated and a cuffed portex tracheostomy tube was placed. Patient was administered intravenous antibiotics and steroids and intra muscular analgesics for 3 days post operatively. Tracheostomy tube was removed on post-operative day 4 and neck strapping done (Fig 6). There was no respiratory distress or stridor after removal of tracheostomy tube. Patient was observed for one day and discharged on post-operative day 5 with oral antibiotics and analgesics. Patient had come for weekly follow ups. Post-operative period was uneventful and the tracheostome closed spontaneously by the end of 4th week (Fig 7). The vocal cord injuries had healed by end of 4th week.

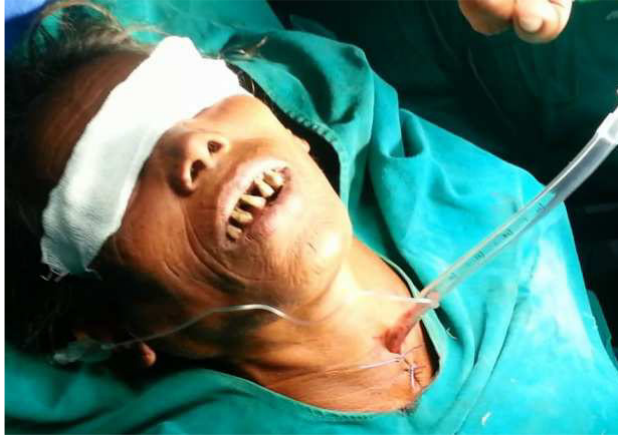

FIGURE 1
TRACHEOSTOME WITH ENDOTRACHEAL TUBE IN SITU

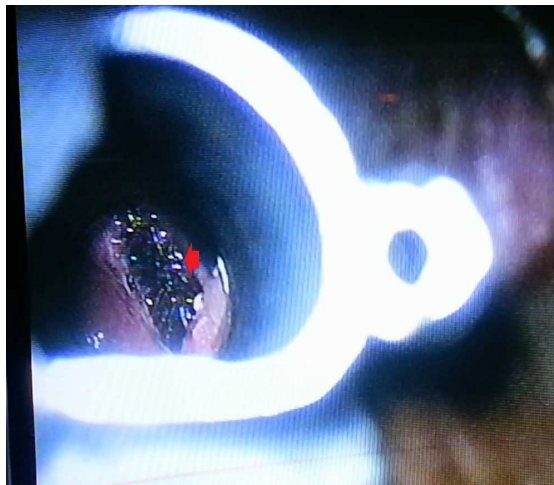


FIGURE 2
MICROLARYNGOSCOPIC VIEW OF GLOTTIS SHOWING FOREIGN BODY IN THE GLOTTIS (ARROW)

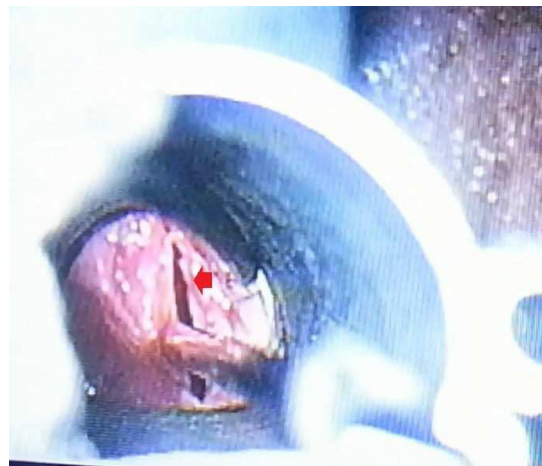

FIGURE 3
MICROLARYNGOSCOPIC VIEW OF GLOTTIS AFTER REMOVAL OF FOREIGN BODY SHOWING LACERATED VOCAL CORD MUCOSA (ARROW).

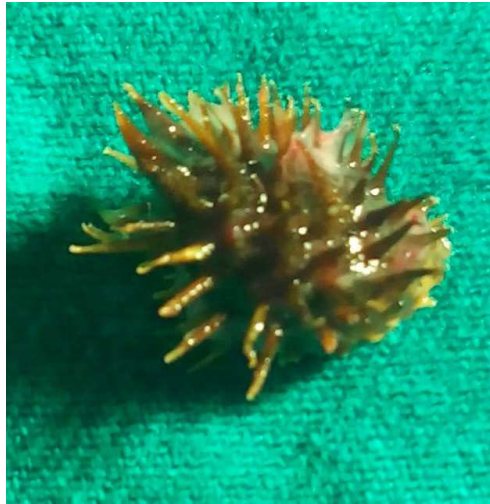

FIGURE 4
FOREIGN BODY (SEED WITH THORNY PROJECTIONS)

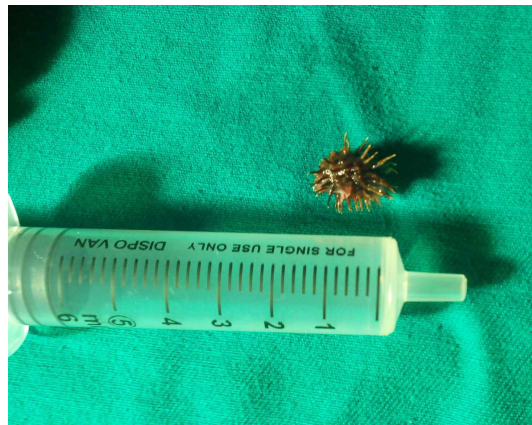

FIGURE 5
DIMENSIONS OF THE FOREIGN BODY MEASURING ABOUT 1CM IN DIAMETER

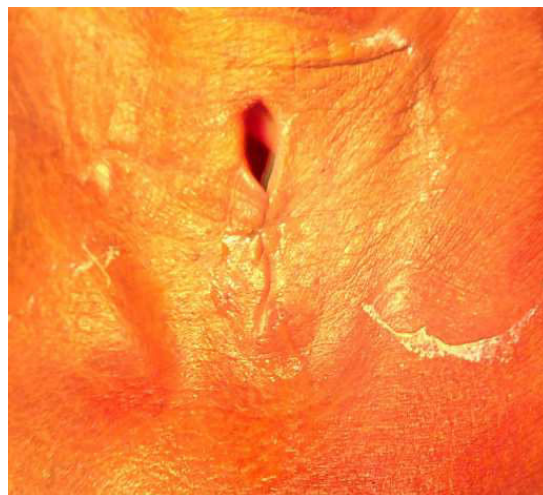


FIGURE 6
TRACHEOSTOMY SITE ON POST OPERATIVE DAY 6

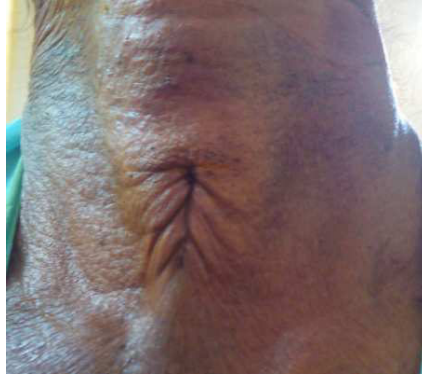

FIGURE 7
TRACHEOSTOMY SITE ON POST OPERATIVE DAY 27

DISCUSSION

Laryngeal foreign bodies present a rare, dramatic circumstance with prevalence rates ranging from 2% to 11% in cases where the airways are involved. Children are affected more frequently, especially between 6 months and 3 years of age³. A foreign body is defined as an object or a substance foreign to the location where it is found. A variety of foreign-bodies have been reported in literature ranging from nuts, seeds, teeth, erasers, pencils, safety-pins, tack pins, whistles, tracheotomy tubes⁴. It is prudent to diagnose aero-digestive foreign bodies as early as possible to minimize potential life-threatening complications in particular glottic foreign body⁴. Subglottic foreign-bodies are however associated with high mortality due to total airway obstruction and hypoxia etc^{5, 6}. However, in many cases it is not easy to make the diagnosis as classical symptoms of choking, wheezing, and decreased breath sounds are absent^{4, 7}. The delay in diagnosis is attributable to patients' behaviour or circumstances where aspiration was unwitnessed⁸. Once the anaesthesia along with muscle relaxants is given, foreign body might fall down to subglottis or trachea which is a more difficult area to deal with⁴. Regardless of history, physical examination and X-ray studies, direct laryngoscopy is the single means of management to rule out or confirm the diagnosis of a laryngeal foreign body, if suspected⁹. A neglected foreign body in the larynx causes laryngeal oedema. Glottic oedema causes sub mucosal infiltration of serous fluid and produces a soft and firm

swelling. It can be translucent if the oedema is due to transudate as in hypersensitivity reaction or opaque if due to inflammatory exudate. Fully developed oedema converts the area to a thick cushion which partly blocks the entrance of larynx¹⁰. Vocal cords and subglottic area may also participate in oedema^{1, 10}. Acute glottic oedema can occur from allergy to the foreign body or local inflammation¹². In local inflammation mucosa may swell due to effusion of fluid¹¹. Local inflammation can be caused by streptococcus or staphylococcus^{10, 12}. Though more frequent in children, epiglottitis may also cause sudden deaths in adults¹³. Majority of inhaled foreign bodies in adults lodge in right bronchial tree because of its width which is more than the left bronchus and the interbronchial septum which projects to the left¹⁴. But in the young children, there is equal distribution of foreign bodies between right and left bronchi because the above mentioned anatomical differences are less pronounced¹⁵. A minority of foreign bodies (< 4%) impact in the larynx¹⁶, that too if they are too large to pass through or if they are of an irregular shape or have sharp edges which can catch on the laryngeal mucosa. the offenders being egg shells, glass fragments or plastics¹⁴. In our case we had a thorny seed which was impacted in the larynx due to its sharp edges. This prevented it from slipping into lower airway in spite of delay in seeking medical attention. Majority of patients of inhaled foreign bodies give a definite history of choking, followed by paroxysmal coughing¹⁷. After the initial paroxysm of cough, the tracheobronchial mucosa becomes tolerant of foreign body and the cough ceases, delaying

the diagnosis^{17, 18}. Other common features are wheeze, predominantly unilateral, unexplained persistent fever, persistent or recurrent lobar pneumonia¹⁴. Acute respiratory distress is uncommon but most alarming presentation seen mainly in laryngeal foreign body¹⁷, which may also manifest as pain in root of neck or over the larynx¹⁴. But the most common difficulty encountered in laryngeal foreign body is the delay in diagnosis¹⁹. In our case, there was no delay in diagnosis from our side. However, patient sought medical attention only after two days of the incident as she was all alone at home. In spite of the delay to seek medical attention, she did not end up in catastrophe as the spaces between the thorns of the seed contributed to the airway and prevented from complete choking. In the removal of foreign bodies, there is no substitute for open rigid endoscopes. Other techniques like pounding the throat and Heimlich's procedures are dangerous, because they may cause further impaction and possible total obstruction not present prior to these attempts¹⁵. We did not try Heimlich's manoeuvre in our patient as we felt it may risk her life. Laryngeal or large tracheal foreign bodies are dealt as direct emergencies with facilities for emergency tracheostomy; these may have to be delivered through the tracheostoma²⁰. In our case, we did not attempt removal of the foreign body through the tracheostoma as it had multiple sharp thorns. We planned for a complete removal of the foreign body with all its thorns intact under direct vision. Laryngeal foreign bodies are usually removed by direct laryngoscopy¹⁵, without any problem, in

majority of cases but in few cases during the induction of anaesthesia, foreign body may cause total respiratory obstruction and may warrant emergency tracheostomy²¹. In our case patient had to undergo emergency tracheostomy as she was in stridor. Emergency tracheostomy and general anaesthesia through the tracheostome gave us space and time for microlaryngoscopy and complete removal of the foreign body from the larynx. The foreign body in this case was unusual in that it had thorny projections all around which facilitated its impaction in the glottis and prevented it from descending into lower airway. Secondly, the spaces between the thorny projections contributed to some airway thus preventing her from getting completely choked even though the foreign body was totally impacted in the larynx. That explains how the patient tolerated the symptoms for 2 days. Thirdly, any hurried removal would have resulted in incomplete removal of the thorns which prompted us to do tracheostomy first before proceeding for microlaryngoscopic removal.

CONCLUSION

Any sudden onset of pulmonary or airway tract sign or symptom should raise the suspicion of inhaled foreign body and warrants an endoscopy. Foreign body aspiration can result in a spectrum of presentations, from minimal symptoms, often unobserved, to respiratory compromise, failure, and even death. Prompt diagnosis and removal of the foreign body is often life saving.

REFERENCES

1. Rezek PR, Millard M. Autopsy Pathology. 1st edn. Charles C Thomas Publishers. Springfield. USA 216-227, (1963)
2. Susan Standring (Ed). Gray's Anatomy-Anatomical Basis of Clinical Practice. 9th edn. Elsevier Churchill Livingstone 638-639,(2006)
3. Flávio Maria Nobre Othon Sidou, João Aragão et al. A rare case of chronic stridor and dysphonia in an adult patient. Braz J Otorhinolaryngol; 78(2):135,(2012)
4. Aayush M, Rahul B, Sunil K, Jatinder K S. Glottic foreign bodies in infants: A series of four cases. Case Reports in Clinical Medicine. Vol.2, No.6, 341-344 (2013)
5. Bachi T. H, Vicky Khattar, Sarika H, Reema Rai. An Unusual Presentation of Impacted Foreign-Body in the Adult Larynx .Indian J Otolaryngol Head Neck Surg,63(1):96–98,(2011).
6. Kumar GK, Ganesan C, Pilai SA, Radhakrishnan E. A subglottic foreign

- body in a child. *Indian J Anaesth* 41(3):207–208,(1997).
7. Reilly J, Thompson J, MacArthur C., Pransky, S., Beste, D., Smith, M., *et al.* Pediatric aero-digestive foreign body injuries are complications related to timeliness of diagnosis. *Laryngoscope*, 107, 17-20, (1997)
 8. Esclamado, R.M. and Richardson, M.A. Laryngotracheal foreign bodies in children, a comparison with bronchial foreign bodies. *American Journal of Diseases of Children*,141, 259-262,(1987).
 9. Sinan Atmaca, Recep Ünal, Teoman Şeşen, Hızır Kılıçarslan *et al.* Laryngeal foreign body mistreated as recurrent laryngitis and croup for one year. *The Turkish Journal of Pediatrics*; 51: 65-66,(2009).
 10. Sharija.S. Sudden Unexpected Death Due To Glottic Oedema -Report of Two Cases. *International Journal of Forensic Science & Pathology*. Vol I (1)(2013.)
 11. Susan Standring (Ed). *Gray's Anatomy-Anatomical Basis of Clinical Practice*. 9th edn. Elsevier Churchill Livingstone 638-639, (2006).
 12. Francis E Camps (Ed). *Gradwohl's legal Medicine*. Bristol John Wright & sons Ltd. 249-250, (1968).
 13. Polson CJ, Gee DJ, Knight B. *The Essentials of Forensic Medicine*. 4th edn. Pargamon Press. New York,557,(1985).
 14. Evans JNG. Foreign bodies in the larynx and the trachea. In: Adams DA, Cinnamond MJ (eds) *Scott-Brown's Paed.Otolaryngology* (6th Ed.) Butlerworth. 1-11, (1997)
 15. Svensson G. Foreign bodies in tracheobronchial tree. Special reference to experience in 97 children. *International J Paediatr Otolaryngol* 61:5-17,(1985)
 16. Cohen SR. Herbert WI, Lewis GB Jr, Geller K. Foreign bodies in the airway. 5 year retrospective study with special reference to management. *Ann Otol Rhinol laryngol*,89:437-42(1980).
 17. Rathmann BF. Boeckmann CR. Foreign bodies in the larynx and tracheobronchial tree in children-a review of 255 cases. *Annals Laryngol* 89:434-436,(1980).
 18. Svensson G. Foreign bodies in tracheobronchial tree. Special reference to experience in 97 children. *International J Paediatr Otolaryngol*, 61:5-17, (1985)
 19. Markowitz D. Gardiner LJ, Sasaki CT. Foreign body aspiration-potential misdiagnosis. *Arch Otolaryngol*;08: 806-07, (1982)
 20. Swensson EE. Reh KH. Kim MC, Brooks /W,Salzberg AM. Extraction of large tracheal foreign bodies through a tracheostoma under bronchoscopic control. *Ann Thorac Surg*; 38: 251-53, (1985)
 21. Parmod Kalsotra, G.B. Kohli, Sudha Kohli, Monica Manhas . Prolonged Impacted Laryngeal Foreign Body. *JK SCIENCE*.Vol 4(4).210-212, (2002).