



Internationally indexed journal

Indexed in Chemical Abstract Services (USA), Index copernicus, Ulrichs Directory of Periodicals, Google scholar, CABI ,DOAJ , PSOAR, EBSCO , Open J gate , Proquest , SCOPUS , EMBASE ,etc.



Rapid and Easy Publishing

The "International Journal of Pharma and Bio Sciences" (IJPBS) is an international journal in English published quarterly. The aim of IJPBS is to publish peer reviewed research and review articles rapidly without delay in the developing field of pharmaceutical and biological sciences



Pharmaceutical Sciences

- Pharmaceutics
- Novel drug delivery system
- Nanotechnology
- Pharmacology
- Pharmacognosy
- Analytical chemistry
- Pharmacy practice
- Pharmacogenomics



Biological Sciences

- Polymer sciences
- Biomaterial sciences
- Medicinal chemistry
- Natural chemistry
- Biotechnology
- Pharmacoinformatics
- Biopharmaceutics
- Biochemistry
- Biotechnology
- Bioinformatics
- Cell biology
- Microbiology
- Molecular biology
- Neurobiology
- Cytology
- Pathology
- Immunobiology

**Indexed in Elsevier Bibliographic Database
(Scopus and EMBASE)**

SCImago Journal Rank 0.288

Impact factor 2.958*

Chemical Abstracts
Service (www.cas.org)



A division of the American Chemical Society

CODEN IJPBJ2



Elsevier Bibliographic databases (Scopus & Embase)

SNIP value – 0.77

SJR - 0.288

IPP - 0.479

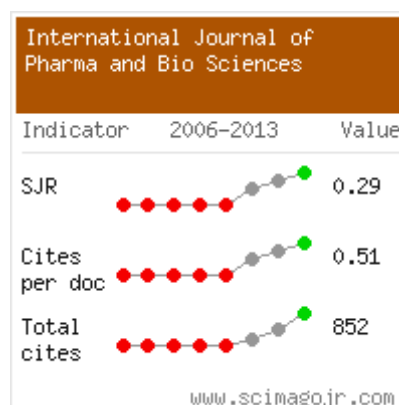
SNIP – Source normalised impact per paper

SJR – SCImago Journal rank

IPP – Impact per publication

Source – www.journalmetrics.com

(Powered by scopus (ELSEVIER))



LUND
UNIVERSITY



JACKSONVILLE STATE UNIVERSITY
Jacksonville State University
Houston Cole Library
USA (Alabama)



Oxford, United Kingdom

INDEX COPERNICUS
INTERNATIONAL

*And indexed/catalogued in
many more university*



*Instruction to Authors visit www.ijpbs.net

For any Queries, visit "contact" of www.ijpbs.net



International Journal of Pharma and Bio Sciences

ISSN
0975-6299

INTESTINAL MALAKOPLAKIA IN A CHILD WITH RARE PRESENTATION

YADAV JK*

**Assistant Professor, Department of pathology. Vijayanagara
Institute Of Medical Sciences, Bellary, Karnataka.*

ABSTRACT

Malakoplakia of the intestine is a rare chronic inflammatory disorder, usually affecting colon and rectum. It is commonly seen in adults. Only few cases have been reported in children. I am presenting a rare case of malakoplakia of large intestine in eight year old boy who presented with multiple polyps in the colon.

KEY WORDS: Intestine, malakoplakia, child, polyps



*Corresponding author



YADAV JK

Assistant Professor, Department of pathology. Vijayanagara
Institute Of Medical Sciences, Bellary, Karnataka.

INTRODUCTION

Malakoplakia is a rare chronic inflammatory disorder of uncertain etiology.¹ Though commonly seen in the urinary tract, it is also reported in other sites like gastrointestinal tract, pancreas, liver, lymph node, respiratory tract, vagina and skin.² It was first time described by Michaelis Gutmann in 1902. One year later Von Hansman coined the term Malakoplakia derived from the greek word malakos(soft) and plakos(plaque).³ Intestinal malakoplakia has been reported in people with wide age spectrum with average age being 47years⁴. It is rare in the paediatric age group and rarely presents as multiple polyposis coli.

CASE REPORT

An eight year old boy was admitted to the hospital with history of intermittent watery diarrhea, bleeding from the rectum and weight loss of seven months duration. He also complained of mass protruding from rectum while passing stools for the past two months. He had jaundice one year back and past history revealed that the patient had a colonic biopsy done earlier in a private hospital for similar complaints which was reported as adenomatous polyp of the colon. On physical examination the child was poorly built, cachectic with mild hepatomegaly. Five tiny polyps were felt on rectal examination. Hematological investigations revealed microcytic hypochromic anemia. Stool microscopy revealed plenty of red blood cells. Chest X ray was unremarkable. Liver function tests were within normal limits. Mild hepatomegaly was detected on abdominal ultrasound. Barium enema showed numerous polypoidal filling defects in the colon.

Videocolonoscopy revealed multiple polyps scattered all over the large intestine (Figure 1a & b). Proctocolectomy with ileoanal anastomosis was done. The resected specimen consisted of terminal ileum, appendix, cecum, colon and rectum measuring 38cms in length. The serosa was unremarkable. The mucosal surface showed 35 pale brown sessile polyps varying from 0.5cms to 3cms in diameter unevenly distributed throughout the large intestine with intervening thickened and thinned out areas (Figure 1c) Microscopy from all the polyps and thickened wall of the colon and rectum showed ulcerated mucosa and submucosa densely infiltrated by sheets of histiocytes, lymphocytes, plasma cells and few eosinophils (Figure 2). The histiocytes had abundant granular eosinophilic cytoplasm. Numerous rounded densely basophilic, laminated, refractile, targetoid Michaelis Gutmann bodies (M-G bodies) were seen both inside the histiocytes and extracellularly. These bodies were positive for Periodic acid Schiff (diastase resistant), Perls Prussian blue and Von kossa stains (Figure 3a,b,c)). The cytoplasmic granules were also highlighted by periodic acid Schiff stain. None of the polyps showed adenomatous features. The muscularis propria, serosa, mesocolon and the draining lymph nodes were unremarkable. Gram and Ziehl Neelsen stains did not show any bacteria. A diagnosis of malakoplakia of large intestine was made. The child was put on trimetoprim-sulphomethoxazole and ascorbic acid for six months but he expired eight months later due to postoperative complications.

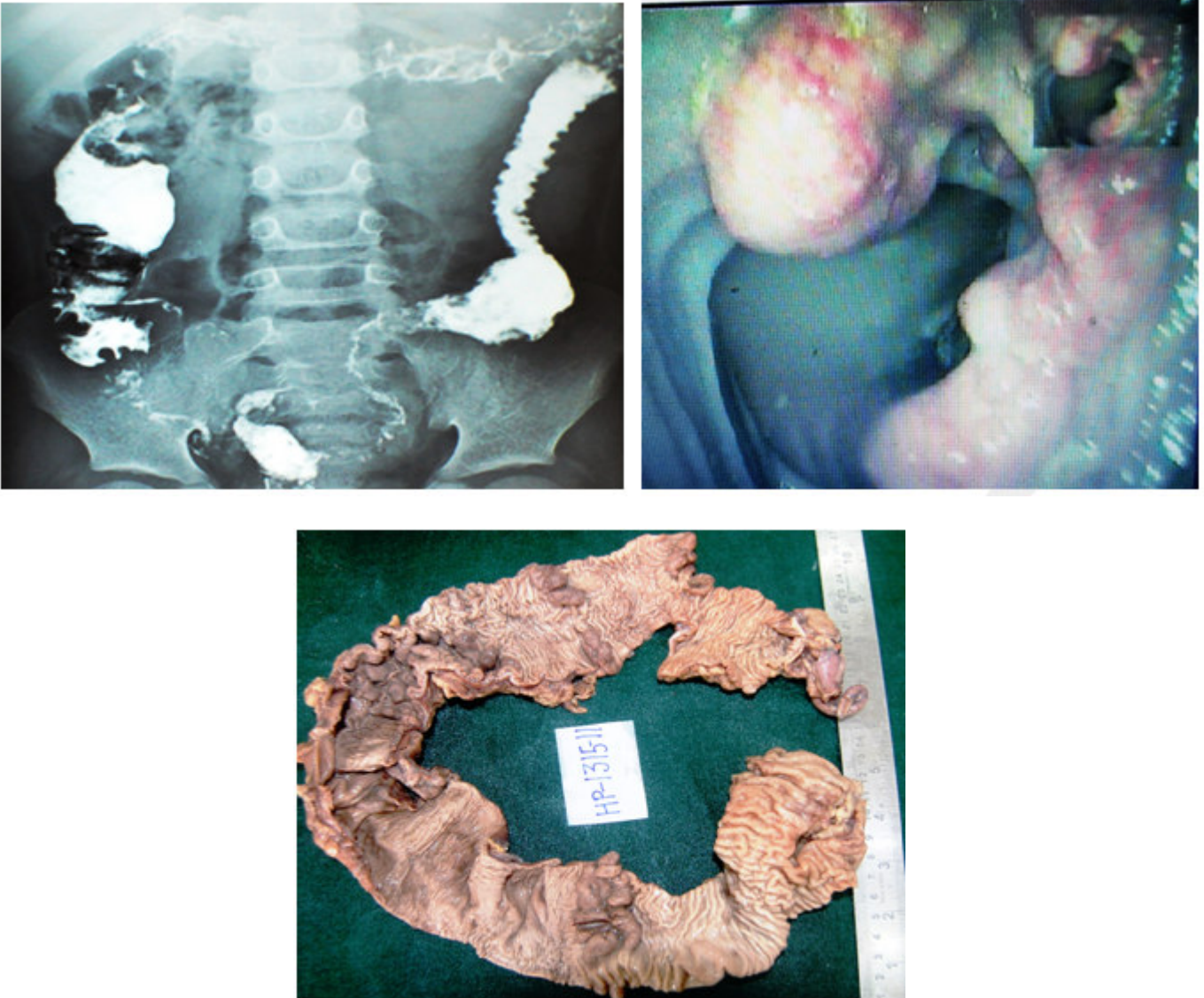


Figure 1

- a) Barium enema showing multiple polypoid filling defects in the colon.***
- b) Videocolonoscopy showing polyps in descending colon .***
- c) Proctocolectomy specimen showing multiple polyps.***

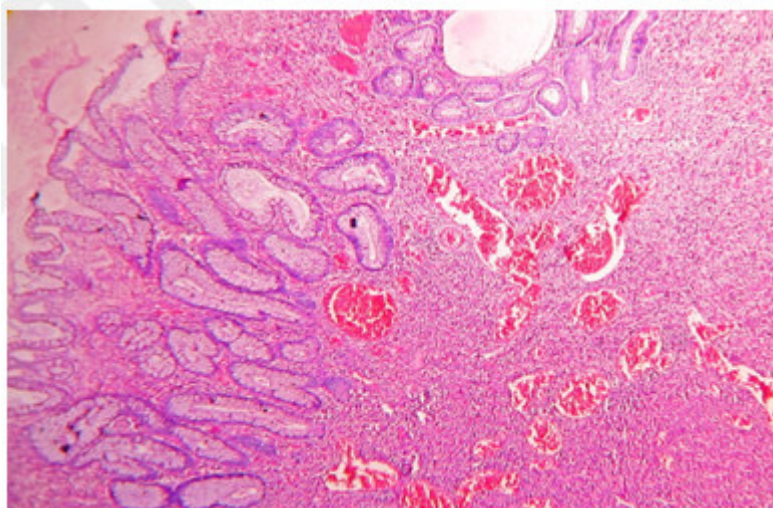


Figure 2
Microphotograph showing colonic mucosa densely infiltrated by histiocytes containing Michaelis Gutmann bodies (H&E 100X)

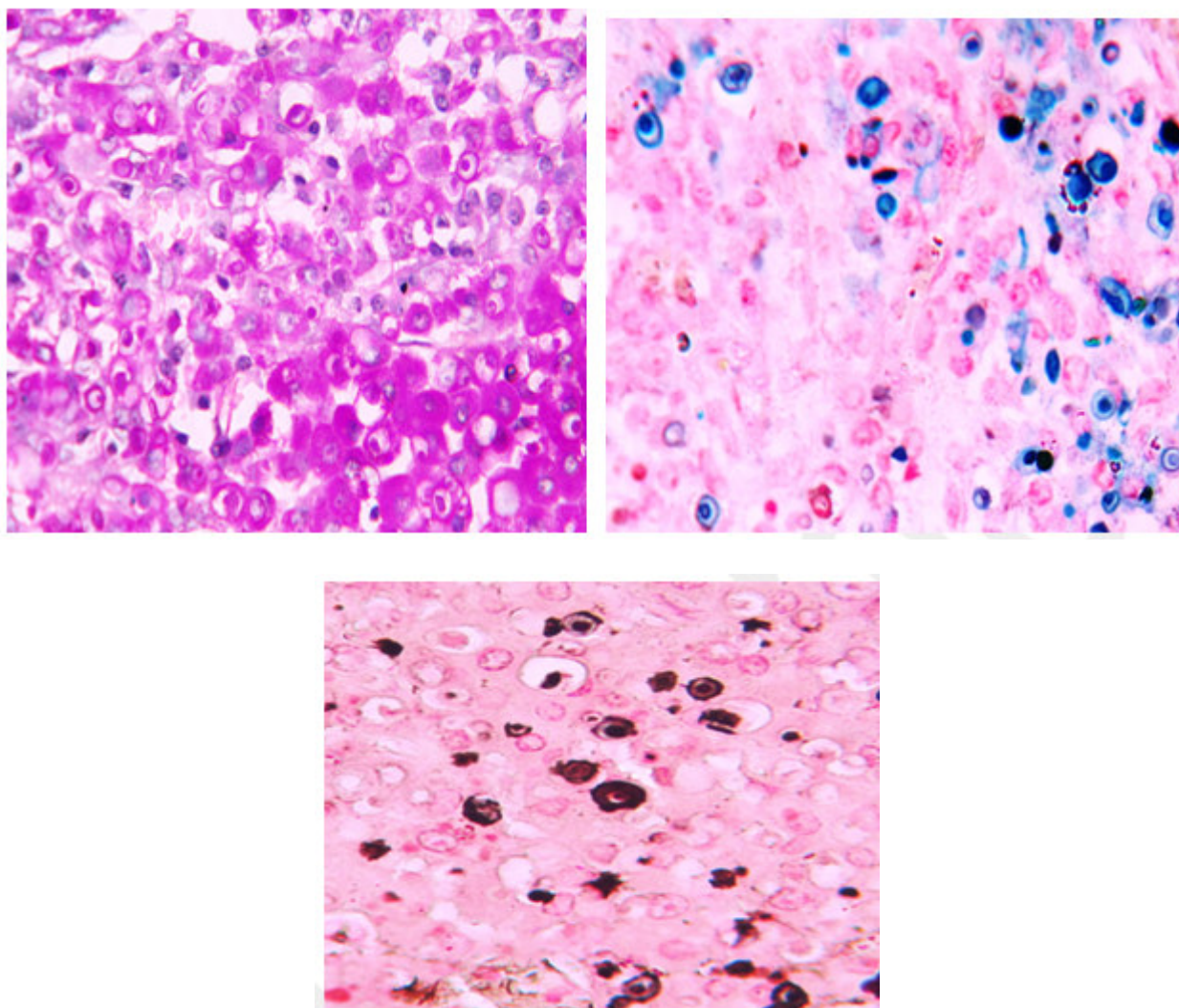


Figure 3
*a)PAS stain b)Perls Prussian stain c)Von kossa stain
Michaelis Gutmann bodies highlighted by special stains*

DISCUSSION

Gastrointestinal tract is the second most common site of involvement by malakoplakia.² It usually involves the descending colon, sigmoid colon and rectum. Endoscopically it appears in three different patterns unifocal mucosal nodules and plaques, multifocal mucosal nodules and polyps, large mass lesions. Colonic malakoplakia was first described by Turner and Lattes in 1965. McCure made a comprehensive review of the world literature on 34 cases of gastrointestinal malakoplakia.⁴ In his study the entire colon was involved only in two cases and polyps were described in six cases. In the present case, the entire colon and rectum were involved by multiple polyps which indicates its rarity. Gastrointestinal malakoplakia in childhood is often associated with immunocompromised states, tuberculosis, myeloid leukemia and celiac disease⁶, unlike in adults where it frequently coexists with colonic adenocarcinoma. It is also reported in previously healthy children. In our case there were no associated lesions. Malakoplakia is a histological diagnosis characterized by aggregates of macrophages called Von Hansemann cells with distinct M-G bodies which are pathognomonic but not necessary for diagnosis.¹⁻³ These bodies are positive for Perls Prussian blue and Von Kossa stains, as they are coated with calcium and iron salts. Periodic acid Schiff stains both M-G bodies and cytoplasmic granules. Ultrastructural evidence suggests that these cells contain phagolysosomal inclusions comprising vesicles, electron dense bodies, membranous lamellae and the crystalline M-G bodies.¹⁰ Disintegrated bacteria have been occasionally observed. Although the exact cause of malakoplakia is not clear, three possible mechanisms have been suggested: 1) role of bacteria like *Escherichia coli*, *Mycobacterium tuberculosis*, *Proteus mirabilis* and

Staphylococcus aureus 2) abnormal or altered immune response 3) abnormal macrophage response because of defective lysosomal function.⁹ This is due to guanosine monophosphate dehydrogenase and beta glucuronidase deficiency which alters the microtubular and lysosomal function leading to incomplete elimination of bacteria from macrophages.¹ Current evidence points to macrophage killing activity.^{6,9} In the present case the Gram and Ziehl-Neelsen stains failed to reveal any bacteria. However complete workup of immunological status was not possible. The early stages of malakoplakia should be differentiated from Whipple disease, Chediak Higashi syndrome, tuberculosis, histiocytic storage disorders, sarcoidosis and fungal infections. In Whipple disease the cytoplasmic granules are Sudan black positive whereas they are negative in malakoplakia. Chediak Higashi syndrome can be differentiated by the presence of giant cytoplasmic granules. In sarcoidosis, Schumann bodies in giant cells may give clue to the diagnosis.³ Special stains may help in excluding tuberculosis and fungal infections. Therapy with antibiotics that concentrate in macrophages (eg, quinolone, trimethoprim-sulfamethoxazole) is associated with a high cure rate. Bethanechol, a choline agonist and ascorbic acid, has been used in combination with antibiotics and surgery. Bethanechol and Ascorbic acid has been used to increase the cGMP and cyclic adenosine monophosphate (cAMP) levels in monocytes, which may represent an effective strategy for therapy.

CONCLUSION

Malakoplakia must be considered in the differential diagnosis in children presenting with chronic diarrhea and bleeding per rectum in appropriate clinical setting so that unnecessary radical surgery can be avoided.

REFERENCES

1. Yousef GM, Naghibi B. Malakoplakia outside the urinary tract. Arch Pathol Lab Med, 131:297-300, (2007).
2. Karasavvidou F, Potamianos SP, Barbanis S, Stathakis E, Psychos A et al. Malakoplakia of colon associated with colonic adenocarcinoma diagnosed in colonic biopsies. World J Gastroenterol, 13(45):6109-6111, (2007).
3. Stanton MJ, Maxted W. Malakoplakia: a study of the literature and current

- concepts of pathogenesis, diagnosis and treatment. J Urol,125(5):139-46,(1981).
4. McClure J. Malakoplakia of the gastrointestinal tract. Postgrad Med J, 57:95-103,(1981).
 5. Divya P, Crasta JA. Pediatric malakoplakia of colon; a report of two cases. Pediatr Surg Int,26:323-25,(2010).
 6. Kianifar H, Sharifi N, Talebi S, Kiani M. Malakoplakia of colon in a child with celiac disease and chronic granulomatous disease. Indian J Gastroenterol,25:323-25,(2006).
 7. Pillay K, Chetty R. Malakoplakia in association with colorectal carcinoma: a series of four cases. Pathology, 24:332-35,(2010).
 8. Farahmand F, Karamy H, Mahjoub F. Intestinal malakoplakia in children. Iran J Peditr,62:115-25,(1995).
 9. Kadli NK, Chandrashekar HR, Dadegal RB. Malakoplakia of colon. Indian j peditr,62:115-25,(1995).
 10. Sinclair-Smith C, Kahn LB, Cywes S. Malakoplakia in childhood. Case report with ultrastructural observations and review of the literature. Arch Pathol,99:198-203,(1975).