



EMPHYSEMATOUS CYSTITIS - CASE REPORT AND IMAGING FEATURES

BASHEER AHAMED*

Department of Radiodiagnosis, Sree Balaji Medical College & Hospital, India

ABSTRACT

Emphysematous cystitis is a rare bacterial infection of the bladder, which results in the presence of gas in the bladder wall, laymen, and surrounding tissues. The most important factors involved in this disease are diabetes mellitus, dysuria and neurogenic bladder, with predominance of female gender. We present a case of a 64 years old female patient, with diabetes mellitus tip 2, who presented in our emergency department with fever, abdominal complaint, oliguria for the last one month. Abdominal CT (computer tomography) revealed gas in the bladder with thickening of bladder wall and formation of an air-fluid level. Laboratory test showed anemia and leukocytosis. Urine culture showed elevated growth of Escherichia coli (E. coli). The diagnosis was emphysematous cystitis and patient started the antibiotic specific therapy.

KEYWORDS: emphysematous cystitis, computer tomography, plain radiography

*Corresponding author



BASHEER AHAMED

Department of Radiodiagnosis, Sree Balaji Medical College & Hospital, India

INTRODUCTION

Emphysematous cystitis is an uncommon condition characterized by the presence of air within the bladder wall and lumen [1]. Diabetes mellitus, dysuria and neurogenic bladder are incriminated as major factors in the appearance of emphysematous cystitis, especially in the elderly women [2]. Sectional imaging plays an important role in diagnosis and accurate assessment of the severity of this condition.

CASE REPORT

A 64-year-old female who was a known case of unbalanced diabetes mellitus type 2 for last 15 years, presented in our Emergency Department with fever, diffuse abdominal complaint and dysuria for the last one month. Her past history included left fibrothorax, diabetic nephropathy, and cholecystectomy one month back. The clinical examination revealed hypertension, obesity, pale skin, asymmetric thorax with absence of respiratory murmur on the left lung, left Charcot foot and trophic ulcer. Investigations showed anemia (Hb 7.9 gm/dl), leukocytosis (total leukocyte count 24200 cells/cmm) with 87% neutrophils. Serum creatinine was 2.1 mg/dl, and urea 93mg/dl which lead to the impossibility of contrast media administration. Urine culture revealed *Escherichia coli* 6×10^5 CFU/ml. In the

Emergency department the patient had abdominal and pelvis ultrasound performed which did not show abnormalities in the parenchymatous organs. The bladder could not be correctly evaluated because of agglutinated bowels and artifacts from bladder wall gas. The lung x-ray revealed massive left pleural calcification and lung fibrosis. Diffuse osteoporosis and tarsal-metatarsal pseudarthrosis of the left foot was noted on plain x-ray. A lung and abdomen CT was carried out, which described intraluminal and intramural gas in the bladder with thickening of bladder wall and formation of an air-fluid level (Figure 1a,b). The diagnosis was emphysematous cystitis. Left fibrothorax with mediastinal retraction, fibrosis and spinal cord air was also noted (Figure 2). The patient was admitted in the hospital. The next day a cystoscopy was conducted which confirmed the diagnosis. The patient underwent antibiotics therapy. A second CT scan was performed after two weeks, which showed decreased but persistent bladder wall emphysema with collapse of the bladder, and the appearance of right pleural effusion (Figure 3 a, b). Urine culture became sterile and laboratory values were normalized. The patient was transferred to the department of diabetes for specific therapy and follow-up.

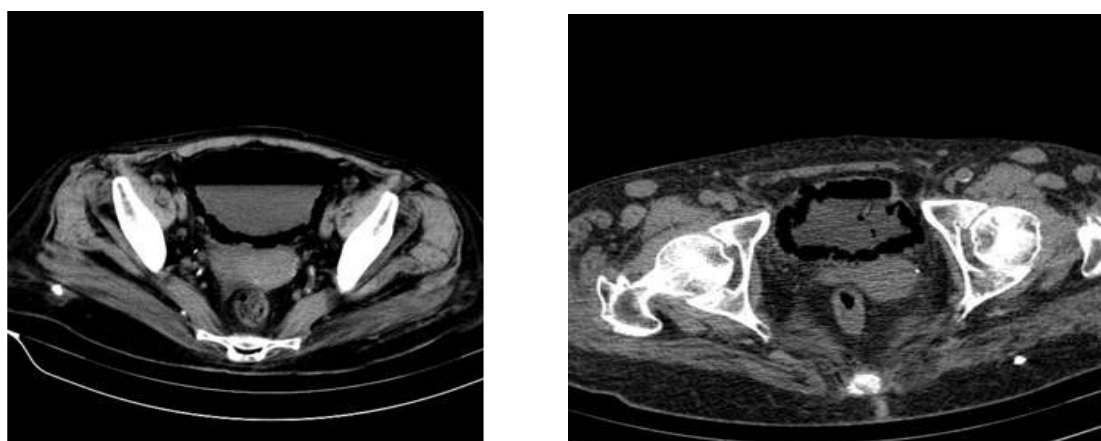


Figure 1
a,b.Lung and abdominal CT showing air in the bladder wall and intraluminal air-fluid level before (a) and after bladder catheter (b);

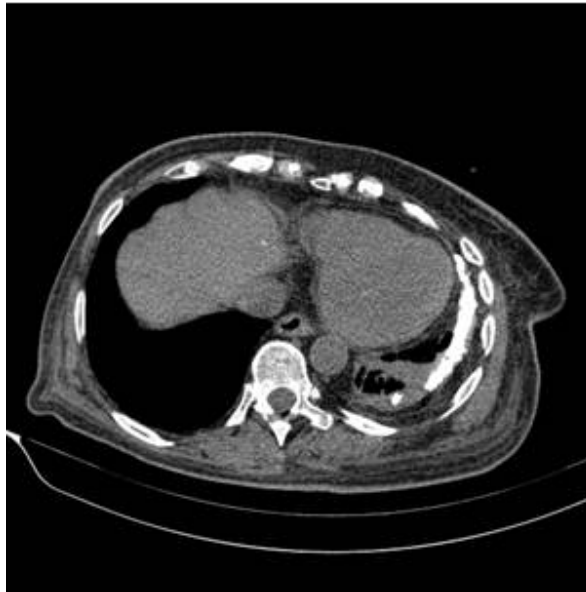


Figure 2

Axial lung CT showing left pleural calcification with mediastinal retraction, fibrosis

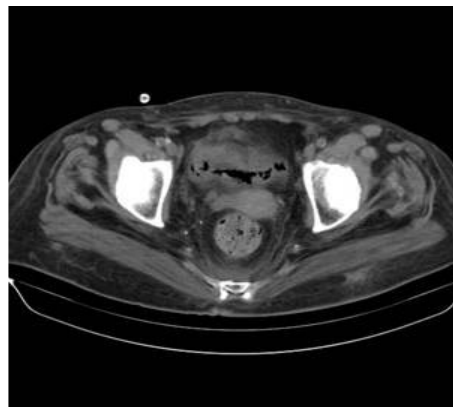


Figure 3

a,b. Axial CT through lung and pelvis after two weeks revealing persistent bladder wall gas, collapse of the bladder

DISCUSSION

Emphysematous cystitis is a rare disease characterized by the presence of gas in and around the bladder wall produced by bacterial or fungal fermentation, *E. coli* being most commonly incriminated [3]. Thomas et al found only 135 cases of emphysematous cystitis between 1956 and 2006 in a review study from 2007 [4]. Emphysematous cystitis is often associated with elderly women. Diabetes mellitus is the most common predisposing factor identified in the literature. The disease is

often also associated with neurogenic bladder, lower urinary tract obstruction, urethral catheter placement, vesicourethral reflux, and renal insufficiency. These factors combined with poorly controlled glycemia levels, place diabetic patients at greater risk of complicated urinary tract infections such as emphysematous cystitis [4,5,6]. The pathology can assess the bladder involvement with evidence of multiple, variably sized gas-filled cavities interspersed in mucosa and muscularis propria and flattened

cells with occasional foreign body type giant cells line the cavities [7]. The mechanism by which gas appears in the wall of the bladder may comprise either elevated tissue glucose levels in diabetic patients, which may provide a more favorable microenvironment for gas-forming microbes or urinary albumin as the substrate for gas production by urinary pathogens. Also vascular compromise and diminished host response and catabolism are thought to be involved in gas production within these tissues. The pathologic and clinical manifestations of emphysematous cystitis are not fully explained by bacterial gas production [8]. The imaging methods play an important role in diagnosis of emphysematous cystitis. Plain x-ray of the abdomen and pelvis can reveal air fluid levels in the bladder or a typical *cobblestone* appearance. A rim of gas lucency outlining the wall of the bladder can suggest the diagnosis, although the presence of bowel gas can be a problematic feature [9]. Computed tomography of the abdomen is superior to plain x-ray as a diagnostic tool because it defines the extent and location of the gas collection more precisely. It can clearly depict air in the bladder lumen or wall, and also the complication of gas presence. CT can differentiate emphysematous cystitis from emphysematous pyelonephritis, in which gas involves the renal parenchyma. The emphysematous pyelonephritis has an increased mortality and generally requires nephrectomy compared with emphysematous cystitis in which surgical intervention is rarely needed [10]. Treatment consists of urinary drainage, antibiotic treatment, and good blood glucose control. Surgical intervention or cystectomy may rarely be needed. Complications of delayed diagnosis may be the extension of infection to the ureters and renal parenchyma, bladder rupture, and death [11].

The gas is reabsorbed once the infection is eliminated. The female patient in the present case was finally diagnosed as having emphysematous cystitis, after imaging investigation. The patient's presenting complaint consisted in abdominal pain, fever and dysuria during the previous 3-4 weeks. She had an extensive medical history uncontrolled diabetes mellitus and the first diagnosis was abdominal or pelvis infection. The abdomen ultrasound performed in the emergency department could not reveal urinary tract infection. Case report has also described air in the spinal cord in association with emphysematous cystitis, but again the pathogenesis not understood. The emphysematous cystitis is almost certainly under-diagnosed as not all patients undergo radiological investigation urinary tract infection and many cases are increasingly discovered following radiological investigation for an entirely different pathology [12]. The routinely use of expensive imaging, however, in septic, diabetic and elderly patients it should be considered in order to minimize complications [13]. On the other hand a delay in diagnosis can lead in life threatening complications, especially in septic, diabetic and elderly patients. Prompt medical therapy is usually sufficient for patient recovery, but they require careful monitoring for the development of complications. In conclusion, the radiology plays an important role in the definitive diagnosis of various conditions responsible for the presence of gas in the urinary tract. Some of these diseases can be life-threatening and needs prompt diagnosis and therapy. When the plain radiography or ultrasound features are inconclusive, CT enables correct diagnosis of the disease, providing accurate localization and guiding the appropriate management.

REFERENCES

1. Quint HJ, Drach GW, Rappaport WD, Hoffmann CJ: Emphysematous cystitis: a review of the spectrum of disease. *J Urol* 1992, 147:134-137.
2. Wong JW, Pace KT. Emphysematous pyelitis, ureteritis and cystitis. *Can Urol Assoc J.* 2010, 4:148-149.

3. Yoshida K, Murao K, Fukuda N, et al. Emphysematous cystitis with diabetic neurogenic bladder. *Intern Med.* 2010; 49:1879-1883.
4. Thomas AA, Lane BR, Thomas AZ, et al. Emphysematous cystitis: a review of 135 cases. *BJU Int* 2007; 100:17–20.
5. Mokabberi R, Ravakhah K. Emphysematous urinary tract infections: diagnosis, treatment and survival (case review series). *Am J Med Sci* 2007; 333:111–116.
6. Grupper M, Kravtsov A, Potasman I. Emphysematous cystitis: illustrative case report and review of the literature. *Medicine* 2007; 86:47–53.
7. Huang JJ, Chen KW, Ruaan MK. Mixed acid fermentation of glucose as a mechanism of emphysematous urinary tract infection. *J Urol.* 1991;146:148–151.
8. Affes N, Bahloul A, Dammak Y, Beyrouti R. Emphysematous cystitis of the diabetic patient. *North Am J Med Sci.* 2009;1:114–116.
9. Grayson DE, Abbott RM, Levy AD, et al. Emphysematous infections of the abdomen and pelvis: a pictorial review. *Radiographics* 2002; 22:543–561.
10. Toyota N, Ogawa D, Ishii K, et al. Emphysematous cystitis in a patient with type 2 diabetes mellitus. *Acta Med Okayama.* 2011; 65:129-133.
11. Chimezie C, Amanambu MD. Emphysematous cystitis-a case report. *Infect Dis Clin Pract.*2008; 16:118–119.
12. Gangadhar P, Gogate YV, Walia R, Bhansali A. Emphysematous cystitis in a patient with type-2 diabetes mellitus. *Indian J Endocrinol Metab.* 2011;15:55-57.
13. Selley JK, Kane BG, Kane KE. Importance of obtaining a detailed medical history in diagnosing emphysematouscystitis. *J Am Osteopath Assoc.* 2010;110:91-4.