



MELATONIN VERSUS OMEGA-3 FATTY ACID AS POSSIBLE ANTIOXIDANTS AGAINST CYCLOPHOSPHAMIDE-INDUCED PULMONARY TOXICITY IN ADULT ALBINO RATS

RAGIA M. HEGAZY ^(1, 2), **EMAN M. FARUK** ⁽³⁾, **FAROUK S. ELGENDY** ⁽¹⁾
AND **ESAM M. MEHLAB** ⁽⁴⁾

1- Department of Forensic Medicine & Clinical Toxicology, Benha Faculty of Medicine, ARE

2--Department of Pharmacology and Toxicology, Faculty of Medicine, UQU, KSA

3- Histology and Cell Biology Department, Benha Faculty of Medicine, ARE

4- Anatomy Department, Benha Faculty of Medicine, ARE

ABSTRACT

Cyclophosphamide (CP) is an anti-neoplastic and immunosuppressive agent used in organ transplantation and treatment of some autoimmune diseases. Melatonin (MT) has immunomodulatory antioxidant effects. Omega-3 is an essential fatty acid used as an antioxidant. The study aimed to compare the antioxidant role of MT versus omega-3 in the pulmonary toxicity of cyclophosphamide in rats. Sixty male rats were divided into four equal groups. Group I (Control group), Group II: was given a single toxic dose of CP (200 mg/kg IP), Group III: was given a melatonin intraperitoneal (10mg/kg/day for two weeks) concomitantly with CP and Group IV: was given fish oil through an intragastric tube (0.5 ml/kg/day for 2 weeks) concomitantly with CP. Histological, immuno- histochemical and biochemical studies had done to the rats' lungs. CP significantly induced oxidative lung damage. In Group III and IV there were significantly decreased lipid peroxidation and alterations in glutathione content (GSH), superoxide dismutase (SOD) and catalase induced by CP in lung tissues. Histological examination of the lungs in group II, revealed inflammatory cell infiltration with interstitial edema, hemorrhage, septal thickening, which markedly reduced in groups III and IV ($P < 0.05$), but this reduction was more marked with omega-3 (group IV). Also, groups III and IV, showed a significant decrease ($P < 0.05$) in cellular infiltration and extravasated RBCs, collagen fibers accumulation and in caspase-3 expression ($P < 0.05$) comparable to group II. Recommendation: concomitant administration of omega-3 with CP is essential as it over melatonin against CP pulmonary toxicity.

KEYWORDS: melatonin; omega-3; cyclophosphamide; lipid peroxidation; glutathione and SOD.



RAGIA M. HEGAZY

Department of Forensic Medicine & Clinical Toxicology, Benha Faculty of Medicine, ARE
Department of Pharmacology and Toxicology, Faculty of Medicine, UQU, KSA

*Corresponding author

INTRODUCTION

Cyclophosphamide is an alkylating agent that is used in combination with other chemotherapeutic agents for the treatment of a variety of malignant processes [1]. It also has immunosuppressive properties and is increasingly used for the treatment of certain autoimmune diseases, either as a sole agent or in combination with glucocorticoids. Long-term use of cyclophosphamide is associated with a multitude of significant side effects, such as hair loss, leukopenia, hemorrhagic cystitis, infertility, the development of secondary malignancies, and pulmonary toxicity. Its cytotoxic effects are the result of chemically reactive metabolites that alkylate DNA and protein, producing cross-links [2-4]. The injury of normal tissues is the major limitation of using CP, which gives rise to numerous side effects [5]. Several studies suggest that antioxidant supplementation can influence the response to chemotherapy as well as the development of adverse side effects that result from treatment with antineoplastic agents [6]. CP and other anticancer drugs have been tried in combination with various detoxifying and protective agents, reducing or eliminating their adverse toxic effects [7, 8]. Melatonin (N-acetyl-5-methoxytryptamine) is synthesized mainly by the pineal gland and is suggested to have antioxidant and protective effects against oxidative stress in several experimental and clinical conditions [9]. Melatonin possesses strong antioxidant activity by which it protects cells, tissues, and organs from the oxidative damage caused by reactive oxygen species, especially the hydroxyl radical ($\cdot\text{OH}$), which attacks DNA, proteins, and lipids and causes pathogenesis [9]. Several investigators believe that melatonin's antioxidant properties are due to its ability to scavenge ROS (Reactive Oxygen Species) and increase cellular antioxidants. Melatonin can quench the peroxy radical, hypochlorous acid, and singlet oxygen, all of which cause cell damage [10–12]. There are some studies reporting the protective effects of this hormone in sepsis in both humans and animals, decreasing the levels of inflammatory cytokines and oxidative stress [12, 13]. This provides direct evidence that melatonin under physiological conditions, acts as a direct free radical scavenger and detoxifies the highly cytotoxic OH in vivo [13, 14]. Omega-3 (ω -3) fatty acids are long-chain, polyunsaturated fatty acids (PUFAs) of plant and marine origin [15]. Because these essential fatty acids cannot be synthesized by the human body, they must be derived from dietary sources. Flaxseed, hemp, canola and walnut oils are rich sources of the parent omega-3, alpha linolenic acid (ALA) [15]. Many studies documented antioxidant, anti-apoptotic and anti-inflammatory effects of fish n-3 fatty acids in various tissues stressed by ischemia reperfusion damage [16, 17]. omega-3 fatty acids play a crucial role in all systems of the body to function normally, including; skin, respiratory system, circulatory system, brain and organs as well as normal growth and development [18]. Hence, the present study was carried out to assess the comparative protective effects of melatonin versus omega3on cyclophosphamide against pulmonary apoptosis and oxidative damage in rats.

MATERIALS AND METHODS

A) Drugs

Cyclophosphamide

was used in the form of an endoxan ampoule of 200 mg (Asta Medica, Germany) a vial was dissolved in 10 ml saline [19].

Melatonin

was used in the form of tablets, 3 mg each (Natures Bounty, USA); each tablet was dissolved in 5% ethanol. The total dose of melatonin was calculated at a dose of 10 mg/kg/day for two weeks [20].

Omega 3

were administered fish oil (menhaden oil; Sigma, St. Louis, Mo. USA) through an intragastric tube, once daily, at a dose of 0.5 ml/kg body weight/day, concomitantly with CP [21].

B) Chemicals

All chemicals were obtained from Sigma–Aldrich Chemie GmbH (Taufkirchen, Germany) and all organic solvents from Merck KGaA (Darmstadt, Germany). All reagents were of analytical grade, were prepared fresh daily (except the phosphate buffer) and stored in a refrigerator at 4 °C. Bovine serum albumin and a kit for protein measurement were purchased from Ziest Chem. Co. (Tehran, Iran).

C) Animals

Sixty male rats weighing 180 ± 10 g were obtained from the animal house, Moshtohor faculty of Veterinary Medicine, Benha University, kept in animals' house of the university animal facility and maintained under a controlled 12 hr light/dark cycle and temperature (24 ± 1 °C). The animals were acclimatized for 1 week before the study and were given standard food pellets and water ad libitum. Sixty male rats were randomly divided into four equal groups each containing 15 rats. Group I (Control group), Group II: was injected with a single toxic dose of CP (200 mg/kg BW, Intra Peritoneal IP), Group III: was injected with melatonin (10 mg/kg IP) per day for two weeks concomitant with single dose of CP and group IV: was administered fish oil through an intragastric tube, once daily, at a dose of 0.5 ml/kg body weight/day, concomitantly with CP for 2 weeks. All animals were killed by an overdose of ether. The right lungs were gently perfused with 10 ml of 0.9% saline to remove blood, and then put in Eppendorf tubes and stored in a freezer at -80°C for biochemical analyses. Left lungs were fixed in 10% formalin.

D) Biochemical analysis**Homogenate preparation**

The Right lungs tissues were washed with saline to remove residual blood, and then placed into tubes, frozen with liquid nitrogen and stored at -70 °C. The frozen lung tissues were homogenized in chilled phosphate buffer (0.1 M, pH 7.4) containing KCl (1.17%), by means of a homogenizer (Heidolph DiAx 900; Heidolph Elektro GmbH, Kelheim, Germany), an electric homogenizer using an ice cooled 20 mM Tris HCl buffer pH 7.4 containing 0.15 M KCl buffer pH 7.4, then centrifuged at 3000 xg for 15 min at 4°C. The supernatant obtained was used freshly for biochemical analysis.

Lipid peroxidation assay

TBARS (thiobarbituric acid reactive substances) in lung tissues was evaluated by reaction with thiobarbituric acid. Briefly, reaction mixture (1.0 mL) was contained 0.1 M of phosphate buffer (0.58 mL; pH 7.4), tissue homogenate (0.2 mL), 100 mM of ascorbic acid (0.2 mL) and 100 mM of ferric chloride (0.02 mL). After incubation at 37°C for 60 min, reaction was stopped by addition of 10% of trichloroacetic acid (1.0 mL). Then, 1.0 mL of thiobarbituric acid (0.67%) was added to the reaction mixture and placed in boiling water bath for 20 min. The amount of thiobarbituric acid reactive substances (TBARS) formed was examined by recording the absorbance of reaction mixture at 535 nm using spectrophotometer against a reagent blank. So, lipid peroxidation was measured with the thiobarbituric acid (TBA) reaction. This method was used to obtain a spectrophotometric measurement of the color produced during the reaction to thiobarbituric acid (TBA) with malondialdehyde (MDA) at 535 nm [22&23].

Reduced glutathione (GSH) level

Reduced glutathione (GSH) was determined spectrophotometrically using glutathione reductase and 5,5'-dithiobis(2-nitrobenzoic acid) as described by [22&23].

Superoxide dismutase (SOD) activity

After the supernatant solution was extracted with an equal volume of ethanol/chloroform mixture (5/3, v/v) and centrifuged at 5000 g for 60 minutes, the upper ethanol phase was taken and used in the superoxide dismutase (SOD). SOD activity was evaluated through the method of previous study [24]. Reaction mixtures contained sodium carbonate (1 ml, 50 mM), nitro blue tetrazolium (0.4 ml, 25 mM), and freshly prepared hydroxylamine hydrochloride (0.2 ml, 0.1 mM). The reaction mixtures were mixed by clear supernatant of tissue homogenates (0.1 ml, 1:10, w/v).

Catalase (CAT) activity

CAT activity was evaluated according to the method of Nabavi et al, 2012[25]. Briefly, a reaction mixture (3 mL) containing 50 mM of phosphate buffer (2.5 mL; pH 5.0), 5.9 mM of H₂O₂ (0.4 mL) and lung homogenate (0.1 mL) was incubated for one min and absorbance of the sample was recorded at 240 nm.

E) Histological study

The left lung lobes were fixed in 10% neutral buffered formalin sliced transversely, paraffin embedded, and prepared as 5- μ m-thick sections that were then stained with hematoxylin and eosin (H&E) for light microscopic evaluation. Three factors (thickening of the alveolar septa, pneumocyte hyperplasia, and infiltration by inflammatory cells) were measured using a semi-quantitative method. The level of damage was recorded based on a graded scale of 0- 4, in which grade 0 = no damage, 1 = very low level of damage, 2 = mild damage, 3 = moderate damage and 4 = severe damage. Slides were viewed and photographed using a camera attached to a microscope (Labomed, LX400) at 400 \times magnification. Masson's trichrome stain for observation of collagen fibers [26] and immune-histochemical detection of caspase-3 using a standard avidin-biotin peroxidase complex system according to the kit used (Neomarkers) followed by diaminobenzidine (DAB) visualization [27]. Sections were counterstained with hematoxylin [28].

Morphometric study

was done by using the image analyzer computer system with Leica Qwin 500 software (Cambridge, England) to determine the following

- a. Area% of the stained collagen fibers per high-power field.
- b. Area% for the distribution of the immune-histo-chemical stains.

F) Statistical analysis

Data were tabulated and analyzed statistically using SPSS software Version 20 (IBM Corp., Armonk, NY, USA). Data are presented as the mean \pm standard deviation (SD). One-way analysis of variance and t-test, with $P < 0.05$ as the level of statistical significance were used for multiple comparisons of data [29].

RESULTS

Lung biochemical oxidant finding

Lipid peroxidation level

Group II (single injection of CP) significantly increased ($P < 0.05$) the lipid peroxidation level of lung homogenates as compared to the control group. In Group III and Group IV there were reduced the elevated level of lipid peroxidation in lung induced with administration of CP (Table 1).

GSH content

The GSH level in lungs of animals treated with CP indicates a reduction as compared to rat in the control group ($P < 0.05$) (Table 1). Administration of melatonin and omega 3 with CP injection significantly restored the GSH level depletion in lung ($P < 0.001$).

SOD activity

The SOD activity in lung homogenates of CP-administered rat was significantly ($P < 0.001$) lower than that of the control group. In the lung homogenates of group III and group IV, activity of SOD was significantly higher than those of the CP group ($P < 0.001$) as illustrated in Table 1.

CAT activity

The CAT activity in lung homogenates of CP-administered rat was significantly ($P < 0.001$) lower than that of the control group (Table 1). In the lung homogenates of melatonin - and omega 3 treated rats with CP injection, activity of CAT was significantly ameliorated toward to the control group ($P < 0.001$).

Histological result**H&E**

The positive control group showed normal histological architecture of lung with many alveoli, bronchioles, septal capillaries and thin inter-alveolar septum (Fig. 1a). Bronchioles had an intact epithelial lining. Alveoli were observed with a thin interalveolar septum and lined with type I pneumocytes with flattened nuclei predominated in the alveolar wall, whereas few type II pneumocytes were observed with their rounded nuclei bulging into the alveolar lumen (Fig. 1b). In the group II (CP group), lung showed small alveolar space, alveolar macrophages with cellular infiltration, congested blood vessels and extravasated red blood cells, and thickened alveolar septa lined with hyperplastic pneumocytes (Fig. 1c&d). In the group III, there was decreased thickening of the interalveolar septum, less congestion of blood capillaries, and few cellular infiltration with widening of air spaces (Fig. 1e&f). Alveolar lung, alveolar spaces, and inter alveolar septa appeared similar to those of the control group with no cellular infiltration in group IV (Fig. 1g).

Masson trichrome

In Masson's trichrome-stained sections in group I, there was minimal amount of collagen fibers within the interstitium of the lung (Fig. 2a); In the group II, there was an extensive accumulation of collagen fibers around alveoli or within the interalveolar septa, especially around bronchioles and blood vessels (Fig. 2b). In the group III, there was minimal in amount of collagen fibers appeared in the interstitium (Fig. 2c). Collagen fibers distribution appeared similar to those of the control group in group IV (Fig. 2d).

Immunohistochemical study

Positive immunohisto-chemical staining of caspase-3 demonstrated as brown cytoplasmic staining (index for the degree of nuclear apoptosis). Negative cytoplasmic staining of caspase-3 was found in cytoplasm of bronchial cells, alveolar and interalveolar septa and along the endothelial lining of blood vessels of control group (Fig. 3a). In the group II, caspase-3 was highly expressed (Fig. 3b), caspase-3 expression was decrease in the group III (Fig. 3c), while in group IV, it was mildly expressed (Fig. 3d).

Morphometric results

The mean area % of collagen fibers accumulation and of caspase-3 expression for all groups was represented in Table (2 and 3). There was a significant decreased ($P < 0.05$) in collagen fibers accumulation and in caspase-3 expression in group III and IV compared with group II. Also, there was a significant decreased ($P < 0.05$) in thickening of the alveolar septa, hyperplasia of pneumocyte and inflammatory cells in groups III and IV compared with group II as in: Table (4).

Table 1

Effects on lung lipid peroxides formation expressed as TBARS, GSH content, SOD and CAT activities in examined groups

Groups	TBARS ^a (nmol MDA eq/g tissue)	GSH ^a (µg/mg protein)	SOD ^a (U/mg protein)	CAT ^a (µmol/min/mg protein)
Group I	38.63±2.21	7.59±0.25	93.28±4.19	46.38±3.24
Group II	78.07±7.39 ^b	4.23±0.03 ^b	48.43±1.07 ^b	28.83±2.69 ^b
Group III	39.47±3.83 ^e	7.89±0.21 ^e	98.26±3.58 ^e	45.88±4.26 ^e
Group IV	36.25±2.41 ^e	7.23±0.57 ^e	95.81±0.34 ^e	44.71±0.431 ^e

Abbreviations: CP= cyclophosphamide; TBARS= thiobarbituric acid-reactive substances; GSH= reduced glutathione; SOD= superoxide dismutase

^aValues are the mean ± standard deviation for each group. ^bP<0.001 compared to the control and ^eP< 0.001 compared with the CP group.

Table 2

The mean area %, SD of collagen fibers accumulation in examined groups

	Group I	Group II	Group III	Group IV
Mean area %	0.15%	25.28%	8.97%	1.65%
SD±	0.0547	4.1645	3.5626	0.5103
P value			0.050	0.033
Significance			S	S

SD = standard deviation

S = Significant at P< 0.05

Table 3

The mean area % of caspase-3 expression and SD in examined groups

	Group I	Group II	Group III	Group IV
Mean area %	0	39.69	12.49	4.67
SD±	0	5.2012	1.3206	0.8210
P value			0.050	0.000
Significance			S	S

SD = standard deviation

S = Significant at P< 0.05

Table 4

Semi-quantitative analysis of histopathological examination in the examined groups

Groups	Group I	Group II ^a	Group III ^a	Group IV ^a
Mean ±SD				
Thickening of the alveolar septa congested blood vessels	0	30.43±2.35 ^b	[†] 7.94±0.95	[†] 11.21±4.1
Infiltration by inflammatory cells	0	21.41±2.31 ^b	[†] 9.61±2.51	[†] 7.32±0.11
	0	61.31±5.35 ^b	[†] 21.41±0.81	[†] 13.11±6.31

^aValues are the mean ± standard deviation for each group. ^bP<0.05 compared to the control and [†]P< 0.05 compared with the CP group.

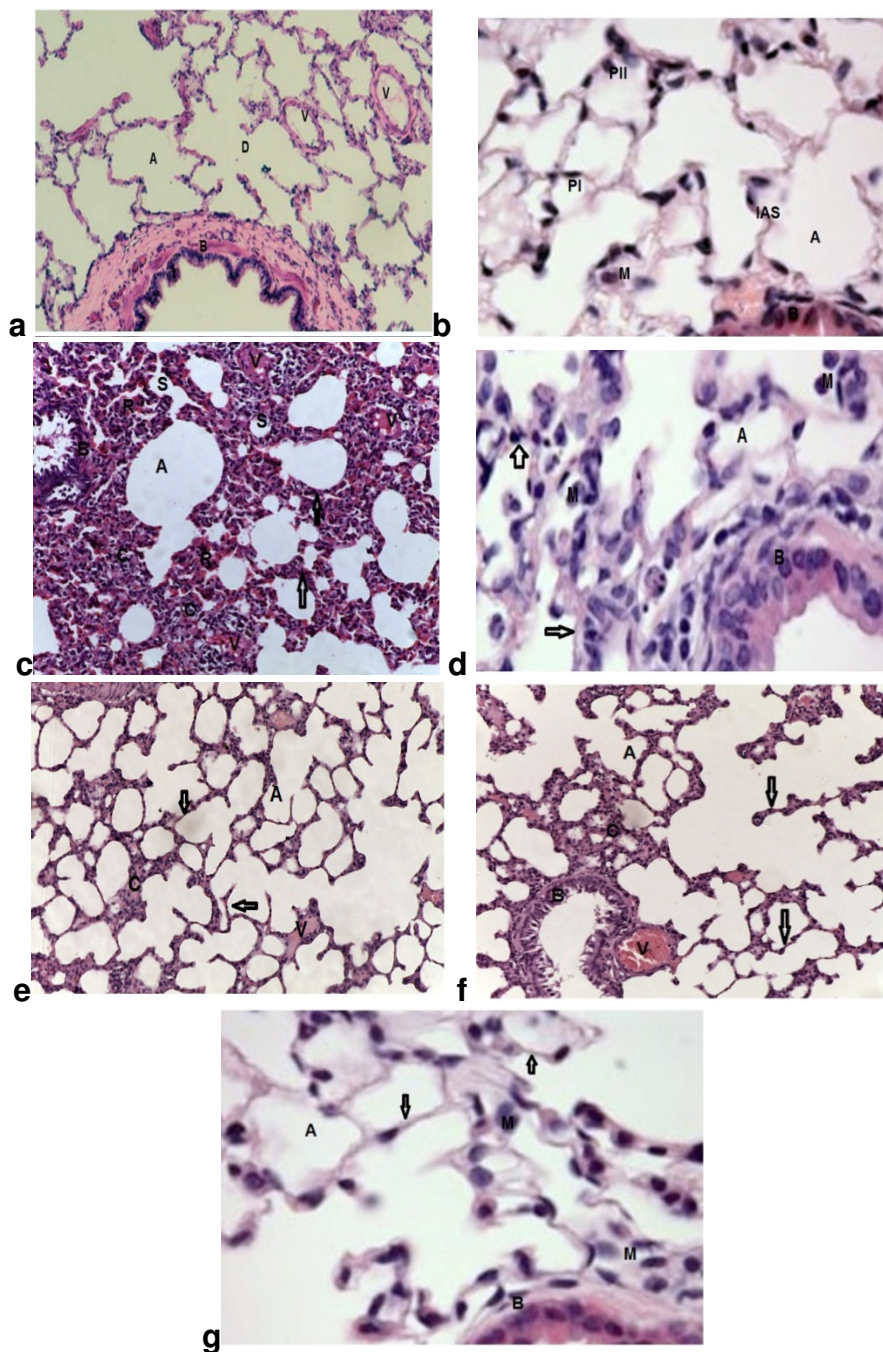


Figure (1) **a.** A photomicrograph of a section in rat lung of group I (control group) showing many alveoli (A), alveolar ducts (D), bronchioles (B) and blood vessels (V), [H&E, X 200]. **b.** A photomicrograph of a more magnified part of a section in the lung of a control rats showing part of bronchiole (B), alveoli (A), and thin inter-alveolar septa (IAS) . The alveoli are lined with pneumocyte type I (PI) and pneumocyte type II (PII). The IAS contains macrophages (M), [H&E, X 400]. **c.** Photomicrograph of a section in rat lung of group II (CP group) showing a bronchiole (B) and alveoli (A) with thick interalveolar septa (arrow), cellular infiltration (C), extravasated RBCs (R). Many narrowed alveolar spaces (S) and congested blood vessels (V). [H&E, X 200]. **d.** A photomicrograph of a more magnified part of a section in the lung of group II (CP group) showing a bronchiole (B) and alveoli (A) with thick interalveolar septa (arrow). Notice presence of many macrophages in the alveoli (M), [H&E, X 400]. **e.** A Photomicrograph of a section in rat lung of group IV (melatonin treated group) showing marked decrease in thickness of interalveolar septa (arrows), less congestion of the blood capillaries (V) with few cell infiltration (C) around the bronchiole (B), alveoli (A), [H&E, X 200]. **f.** A Photomicrograph of a section in rat lung of group III showing many alveoli (A) with apparently thin interalveolar septa (arrow). Notice cellular infiltration (c) and congested blood vessels (V), [H&E, X200]. **g.** A photomicrograph of a more

magnified part of a section in the lung of group IV showing a bronchiole (B) and alveoli (A) with decrease in thickness of interalveolar septa (arrows). Notice presence of macrophages in the alveoli (M), [H&E, X 400].

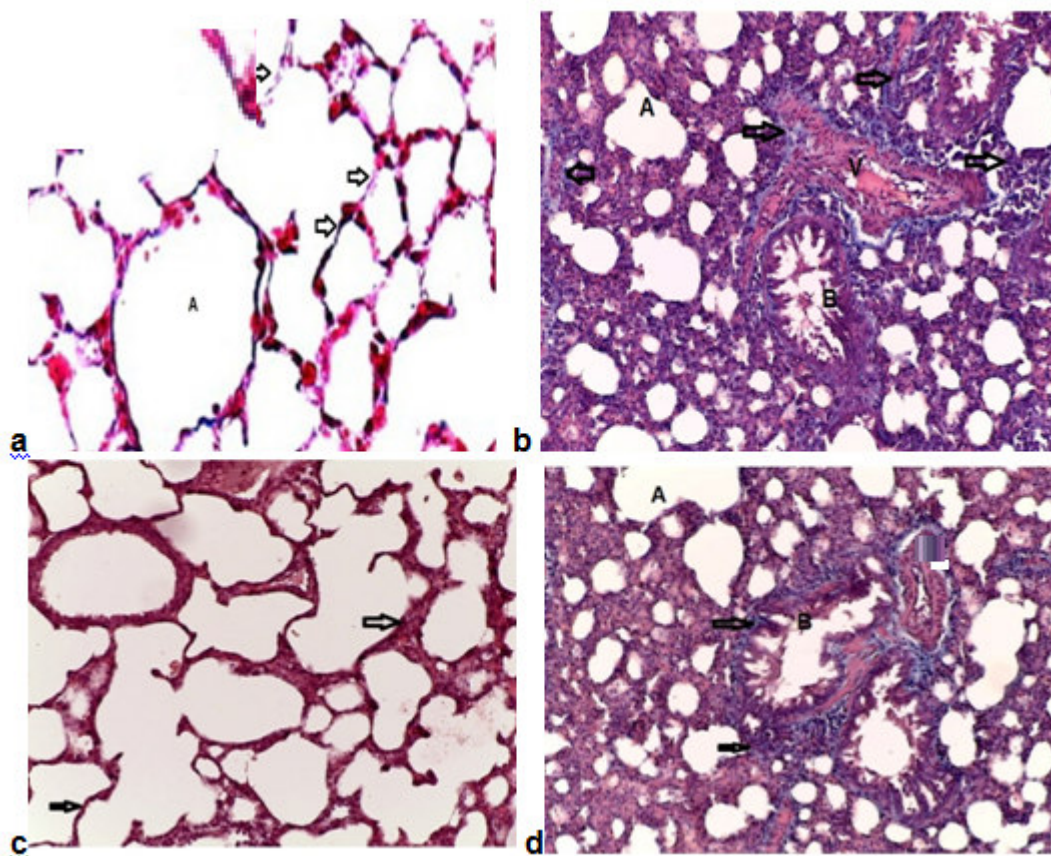


Figure (2) a. A Photomicrograph of a section in rat lung of group I (control group) showing the alveoli (A) with the presence of minimal amount of collagen fibers (arrows) in the interalveolar septa. b. A Photomicrograph of a section in rat lung of group II (CP group) showing marked increase in the amount of collagen fibers (arrows) around the bronchioles (B), blood vessels (V) and alveoli (A). c. A Photomicrograph of a section in rat lung of group IV (melatonin treated group) showing the alveoli (A) with decrease in the amount of collagen fibers (arrows) in the interalveolar septa and the walls of the bronchioles (B). d. A Photomicrograph of a section in rat lung of group III (melatonin group) showing minimal amount of collagen fibers in interalveolar septa (arrows). [Masson's trichrome, × 200].

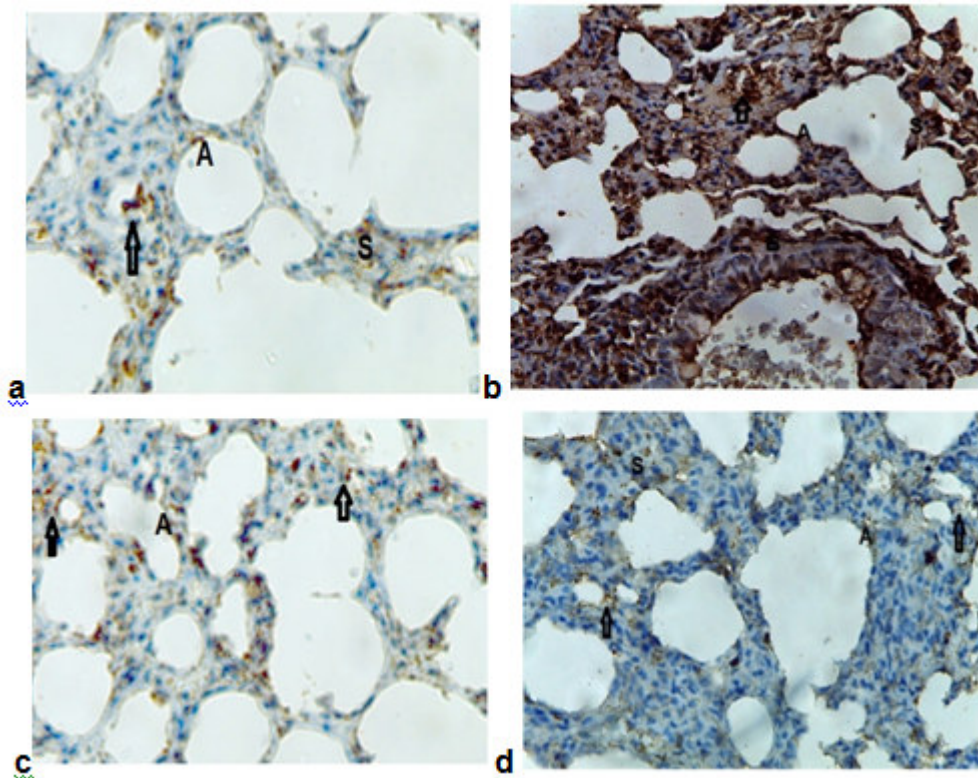


Figure (3) a. A Photomicrograph of a section in rat lung of group I (control group) showing negative caspase-3 immuno staining of cytoplasm of alveolar (A) ,interalveolar septal cells(S) and along the endothelial lining of blood vessels(arrows).b. A Photomicrograph of a section in rat lung of group II (CP group) showing highly caspase-3 expression in cytoplasm of alveolar cells(A), bronchial cells (B), interalveolar septal cells (S)and along the endothelial lining of some blood vessels (arrows). **b.** A Photomicrograph of a section of rat lung of group III (melatonin group) showing minimal caspase-3 expression in cytoplasm of alveolar cells (A), septal cells and along the endothelial lining of some blood vessels (arrows).**c.** A Photomicrograph of a section in rat lung of group IV (melatonin treated group) showing mild to moderate caspase-3 expression in cytoplasm of alveolar cells (A), septal cells (S) and along the endothelial lining of some blood vessels (arrows). **d.** A Photomicrograph of a section in rat lung of group III (melatonin group) showing minimal caspase-3 expression in cytoplasm of alveolar cells (A), septal cells and along the endothelial lining of some blood vessels (arrows).[caspase-3 immuno staining X 400]

DISCUSSION

The current study evaluated the possible protective effect of Omega-3 oil as natural antioxidant Vs melatonin against pulmonary toxicity induced by CP. Cyclophosphamide is effective against a wide spectrum of malignancies, such as leukemia, lymphoma, breast, lung, prostate, and ovarian cancers[30]. Cancer patients usually suffer from lung toxicity after CP therapy that is characterized by hypoxemia, non-cardiogenic pulmonary edema, low lung compliance, and widespread capillary leakage [31].

Several studies indicate that CP has a pro-oxidant character, and generation of oxidative stress after CP administration leads to decrease in the activities of antioxidant enzymes and increase in lipid peroxidation in lung of animals [32]. Induction of lipid peroxidation has been reported in different tissues of experimental animals after CP administration [33, 34]. CP and its metabolite acrolein cause inactivation of microsomal enzymes and result in increased ROS generation and lipid peroxidation [33, 34]. Hence, the present study was also carried out to assess the toxic oxidants effects of CP, as well as the antioxidants effect of melatonin and omega 3 on the level of lung antioxidants, lipid peroxidation and histological changes of male rat. The lung antioxidant system disturbances observed in response to CP administration were characterized by changes in

enzymatic and non enzymatic antioxidant parameters. In this study after CP injection, the lung SOD and glutathione reductase activities were decreased, while glutathione peroxidase activity was increased and this were in agreement with [35,36].

The reduced activity was probably connected with damage to the structure of these proteins molecules by reactive oxygen forms or aldehydes generated during CP metabolism. Cellular proteins are susceptible to free radical oxidative modification which can have a significant impact on cellular function [37]. GSH is the principal intracellular nonenzymatic antioxidant. It can detoxify toxic endogenous and exogenous substances, including free radicals and xenobiotics[38]. In this study, administration of CP decreased the GSH content in lung by about 92%. This could be due to the decreased expression of this antioxidant during bronchial cellular damage [39]. This is in accordance with other reports that demonstrated GSH reduction or depletion following CP challenging in animals [38&39]. However, administration of melatonin or omega 3 with CP showed a significant inhibition effect on the GSH level depletion compared to only CP-treated group. The present work also shows that the changes in GSH are accompanied by a concomitant decrease in the activity of antioxidant enzymes namely SOD and CAT following CP administration. SOD and CAT are present in all oxygen-metabolizing cells and their function is to provide a defense against the potentially damaging activity of superoxide and hydrogen peroxide. SOD detoxifies the superoxide radicals to H₂O₂, which has been eliminated by CAT [40].

In the present study, a single administration of 200 mg/kg CP significantly depleted the SOD and CAT activities in lung tissues. However, treatment of melatonin significantly elevated the SOD and CAT level activities, suggesting that it had the ability to restore the activities of the enzyme. The results are in accordance to Shokrzadeh et al., 2014 [41]. In our study, omega-3 oil concurrent-treatment with CP showed a significant reduction in developing free radicals induced lung injury in comparison to melatonin antioxidants effects. Our results indicated that using omega-3 as a concurrent treatment is preferable antioxidants than using it as a post treatment with CP. Our results are inconsistent with, Arunabh et al., 2003[42]. In the present study, CP-treated animals showed lung injury as evidenced by histological findings which included endothelial cell destruction, type I and type II alveolar epithelial cell damage, alveolitis, alveolar edema, hemorrhage and extensive infiltration by inflammatory cells. Sulkowska et al, 2002[43] demonstrated that congestion and edema may be due to the changes produced by CP in epithelial cell structure as well as alveolo-capillary permeability.

Treatment with melatonin showed that the lung damage was minimal with no areas of intralobular necrosis or significant inflammatory infiltration in lung. On application of the immune-histochemical stain, there were clear apoptotic changes in the cytoplasm of the lung cells which are decreased by melatonin administration. These changes were in agreement with those reported by some authors who found that CP induced vascular congestion, inflammatory cell infiltration, and edema. They reported the precise mechanism by which CP causes toxicity: CP can disrupt the redoxbalance of tissues, leading to oxidative stress. They attributed these changes to oxidative DNA damage caused by the hydrogen peroxide derivative of CP through the generation of H₂O₂. In addition, acrolein(a major CP metabolite) is produced, which interferes with the tissue antioxidant defense system and produces highly reactive oxygen free-radicals that are mutagenic to mammalian cells [44,43]. Many studies have explained the possible mechanism of melatonin protection as being dependent on its anti oxidative action. Lena and Subramanian [45] reported that melatonin has the ability to scavenge up to four or more reactive species, which makes melatonin a potent antioxidant and a free radical scavenger. They concluded that melatonin could control the oxidative abuse by (i) directly scavenging a variety of radicals and ROS, (ii) inducing anti oxidative enzymes which reduce the steady state levels of ROS, (iii) inhibiting nitric oxide synthase, which generates nitric oxide, and (iv) stabilizing cell membranes that aid them in reducing oxidative damage [45, 46].

In the present study, the production of malondialdehyde (MDA), which is an index of lipid peroxidation, was increased significantly in lung homogenate compared to control group after CP administration and high significantly decreased by omega-3 administration. This observation is in accordance with many reports that demonstrated apparent elevation in lung TBARS following the administration of CP [30,31&34]. This activity could be due to the ability of omega 3 to scavenge the free radicals generated during oxidative stress induced by CP where omega 3 efficiently inhibited lipid peroxidation [46, 47]. Linoleic acid, a polyunsaturated fatty acid present in omega-3 oil, is known to increase membrane fluidity and allows for osmosis, intracellular and extra cellular gaseous exchange. It is easily susceptible to lipid peroxidation [48].

Finally, in this study, it was found that omega three and melatonin could provide protection against CP-induced lung injury with more effectiveness of omega-3. Several clinical trials should be conducted in the future to combine melatonin treatment with other chemotherapeutic and toxic drugs to reduce their apoptotic cellular changes and toxicity.

Conflicts of interest

There is no conflict of interest to declare

REFERENCES

1. Baumann F, Preiss R. Cyclophosphamide and related anticancer drugs. *J Chromatogr B: Biomed Sci Appl*; 764: 173-192, (2001).
2. Segura A, Yuste A, Cercos A, et al. Pulmonary fibrosis induced by cyclophosphamide. *Ann Pharmacother*; 35:894,(2001)..
3. Malik SW, Myers JL, DeRemee RA, Specks U. Lung toxicity associated with cyclophosphamide use. Two distinct patterns. *Am J Respir Crit Care Med* 1996; 154:1851.
4. Becker CD, Gil J, Padilla ML. Idiopathic pleuroparenchymal fibroelastosis: an unrecognized or misdiagnosed entity? *Mod Pathol*; 21:784, (2008)..
5. A. Ahmadi, S. J. Hosseinimehr, F. Naghshvar, E. Hajir, and M. Ghahremani, Chemoprotective effects of hesperidin against genotoxicity induced by cyclophosphamide in mice bone marrow cells, *Archives of Pharmacal Research*; 31(6) 794–797, (2008)..
6. Hosseinimehr SJ, Ahmadashrafi S, Naghshvar F, Ahmadi A, Ehasnalavi S and Tanha M. Chemoprotective effects of *Zataria multiflora* against genotoxicity induced by cyclophosphamide in rat bone marrow cells. *Integr Cancer Ther*; 9: 219-23, (2010).
7. Mei L., Qin Z. Changwei H., John P., Zhiming K, Yibin C. Protective effects of eicosapentaenoic acid on genotoxicity and oxidative stress of cyclophosphamide in mice. *Environmental Toxicology*; 26(3): 217–223, (2011).
8. Taha NR, Amin HA, Sultan AA. The protective effect of *Moringa oleifera* leaves against cyclophosphamide-induced urinary bladder toxicity in rats. *Tissue Cell*; 47(1):94-104, (2015).
9. Anisimov VN, Popovich IG, Zabezhinski MA, Anisimov SV, Vesnushkin GM, Vinogradova IA. Melatonin as antioxidant, geroprotector and anticarcinogen. *Biochim Biophys Acta*; 1757:573-589, (2006).
10. Agapito MT, Antolín Y, del Brio MT, López-Burillo S, Pablos MI, Recio JM. Protective effect of melatonin against adriamycin toxicity in the rat. *J Pineal Res*; 31(1):23-30, (2001).
11. Mohammad Shokrzadeh, Amirhossein Ahmadi, Farshad Naghshvar, Aroona Chabra, and Mehdi Jafarnejhad. Prophylactic Efficacy of Melatonin on Cyclophosphamide-Induced Liver Toxicity in Mice *BioMed Research International* ;2014 (2014), Article ID 470425:1-6, (2014).
12. Amin Karimian MS, Amirhossein Ahmadi. The potential chemoprotective effects of melatonin against genotoxicity induced by diazinon in human peripheral blood lymphocytes. *Toxicology and Industrial Health*. 2013.
13. A. Karamian, M. Shokrzadeh, and A. Ahmadi, The potential chemoprotective effects of melatonin against genotoxicity induced by diazinon in human peripheral blood lymphocytes, *Toxicology and Industrial Health*, 2013 Oct 4. [Epub ahead of print]

14. Chabra, M. Shokrzadeh, F. Naghshvar, F. Salehi, and A. Ahmadi, Melatonin ameliorates oxidative stress and reproductive toxicity induced by cyclophosphamide in male mice, *Human & Experimental Toxicology*, 33: 185–195, (2014).
15. Holub B.J. Clinical nutrition: 4. Omega-3 fatty acids in cardiovascular care. *C. M. A. J.*; 166: 608-615, (2002).
16. Sarsilmaz M, Songur A, Ozyurt H, Kus I, Ozen OA, Ozyurt B, Sogut S, Akyol O Potential role of dietary omega-3 essential fatty acids on some oxidant/antioxidant parameters in rats' corpus striatum. *Prostaglandins Leukot Essent Fatty Acids*; 69:253–259, (2003).
17. Wall R., Ross R.P., Fitzgerald G.F., and Stanton C. Fatty acids from fish: the anti-inflammatory potential of long-chain omega-3 fatty acids. *Nutr. Rev.*; 68 (5): 280–9, (2010).
18. Berbert A.A.; Kondo C.R. and Almendra C.L. Supplementation of fish oil and olive oil in patients with rheumatoid arthritis. *Nutrition*; 21:131-136, (2005).
19. Kaur K, Michael H, Arora S, Harkonen PL, Kumar S. Studies on correlation of antimutagenic and antiproliferative activities of *Juglans regia* L. *J Environ Pathol Toxicol Oncol*; 22: 59-67, (2003).
20. Rezzani R, Buufoli B, Rodella L et al. Protective role of melatonin in cyclosporine A-induced oxidative stress in rat liver. *Int. Immunopharmacol.*; 5: 1397–405, (2005).
21. Uygur R, Yagmurca M, Alkoc OA, Genc A, Songur A, Ucok K, Ozen OA. Effects of quercetin and fish n-3 fatty acids on testicular injury induced by ethanol in rats. *Andrologia*. doi:10.1111/and.12085 , (2013) [Epub ahead of print].
22. Dundar, K., Topal, T., Ay, H., Oter, S., Korkmaz, A., Protective effects of exogenously administered or endogenously produced melatonin on hyperbaric oxygen-induced oxidative stress in the rat brain. *Clin. Exp. Pharmacol. Physiol.* 32, 926–930, (2005).
23. Mollaoglu, H., Topal, T., Ozler, M., Uysal, B., Reiter, R.J., Korkmaz, A., Oter, S. Antioxidant effects of melatonin in rats during chronic exposure to hyperbaric oxygen. *J. Pineal Res.* 42, 50–54, (2007).
24. Chabra A, Shokrzadeh M, Naghshvar F, Salehi F and Ahmadi A. Melatonin ameliorates oxidative stress and reproductive toxicity induced by cyclophosphamide in male rat. *Hum Exp Toxicol.* 2013.
25. Nabavi SM, Nabavi SF, Eslami S and Moghaddam AH. In vivo protective effects of quercetin against sodium fluoride-induced oxidative stress in the hepatic tissue. *Food Chemistry*; 132: 931-5, (2012).
26. Bancroft JD and Layton C: The Hematoxylin and eosin. In: Suvarna SK, Layton C and Bancroft JD editors. *Theory & Practice of histological techniques*. 7th ed., Churchill Livingstone of El Sevier. Philadelphia. Ch. 10 and 11 PP. 172 - 214, (2013).
27. Jackson P and Blythe D: Immunohistochemical techniques. In: Suvarna SK, Layton C and Bancroft JD editors. *Theory & Practice of histological techniques*. 7th ed., Churchill Livingstone of El Sevier. Philadelphia. Ch. 18 PP. 381 - 434, (2013).
28. Bayomy NA, Abd-Elmagyed ER and Tawfik SM: Effect of Leflunomide (Avara) Drug on the Lung of Adult Male Albino Rats: A Histological and Immunohistochemical Study. *Egypt J. Histol.* 31(2): 278-282, (2008).
29. Wilcox RR. *Basic statistics: understanding conventional methods and modern insights*. 1st ed. Oxford, New York: Oxford University Press; 210–230, (2009).
30. T. S. Khan, A. Sundin, C. Juhlin, E. Wilander, K. Öberg, and B. Eriksson, Vincristine, cisplatin, teniposide, and cyclophosphamide combination in the treatment of recurrent or metastatic adrenocortical cancer. *Medical Oncology* ; 21(2): 167–177, (2004).
31. Beynat-Mouterde C, Beltramo G, Lezmi G, et al. Pleuroparenchymal fibroelastosis as a late complication of chemotherapy agents. *Eur Respir J*; 44:523, (2014).
32. Selvakumar E, Prahalathan C, Mythili Y and Varalakshmi P. Mitigation of oxidative stress in cyclophosphamide-challenged hepatic tissue by DL- α -lipoic acid. *Molecular and cellular biochemistry*; 272: 179-85, (2005).
33. Uchida K. Current status of acrolein as a lipid peroxidation product. *Trends Cardiovasc Med*; 9: 109-13, (1999).

34. Stankiewicz A, Skrzydlewska E and Makiela M. Effects of amifostine on liver oxidative stress caused by cyclophosphamide administration to rats. *Drug Metabol Drug Interact.*; 19: 67-82, (2002).
35. Ali O, Gaffari T, Mustafa S., Fatih S., Ahmet A. Toxic Effect of Cyclophosphamide on Sperm Morphology, Testicular Histology and Blood Oxidant-Antioxidant Balance, and Protective Roles of Lycopene and Ellagic Acid. *Basic & Clinical Pharmacology & Toxicology*; 107 (3): 730–736, (2010).
36. Gebicki S and Gebicki JM. Formation of peroxides in amino acids and proteins exposed to oxygen free radicals. *Biochem J.*; 289: 743-9, (1993).
37. McDiarmid MA, Iype PT, Kolodner K, Jacobson-Kram D and Strickland PT. Evidence for acrolein-modified DNA in peripheral blood leukocytes of cancer patients treated with cyclophosphamide. *Mutat Res.*; 248: 93-9, (1991).
38. Chad K. and Darryn W. The Antioxidant Role of Glutathione and N-AcetylCysteine Supplements and Exercise-Induced Oxidative Stress. *Journal of the International Society of Sports Nutrition.*; 2(2): 38-44, (2005).
39. Kachel DL, Martin WJ 2nd. Cyclophosphamide-induced lung toxicity: mechanism of endothelial cell injury. *J Pharmacol Exp Ther.*; 268:42, (1994).
40. Chakraborty P, Sk UH, Murmu N, Das JK, Pal S and Bhattacharya S. Modulation of cyclophosphamide-induced cellular toxicity by diphenylmethyl selenocyanate in vivo, an enzymatic study. *J Cancer Mol.*; 4: 183-9, (2009).
41. M. Shokrzadeh, A. Chabra, F. Naghshvar, A. Ahmadi, M. Jafarinejhad, and Y. Hasani-Nourian, Protective effects of melatonin against cyclophosphamide-induced oxidative lung toxicity in mice, *Drug Research*, 2014.
42. Arunabh B. Richard A. Aparna K. Khaliquz Z. Dongxu S. Gabriel F. Effect of Dietary n-3 and n-6 Oils with and without Food Restriction on Activity of Antioxidant Enzymes and Lipid Peroxidation in Livers of Cyclophosphamide Treated Autoimmune-Prone NZB/W Female Mice. *Journal of the American College of Nutrition*; 22(5):388-399, (2003).
43. Sulkowska M, Skrzydlewska E, Sobaniec-Lotowska M, et al. Effect of cyclophosphamide-induced generation reactive oxygen forms on ultrastructure of the liver and lung. *Bulletin-veterinary institute in pulawy*; 46: 239-46, (2002).
44. Suddek GM, Ashry NA and Gameil NM. Thymoquinone attenuates cyclophosphamide-induced pulmonary injury in rats. *Inflammopharmacology*. 2012.
45. Lena PJ, Subramanian P. Evaluation of the antiperoxidative effects of melatonin in ammonium acetate-treated wistar rats. *Pol J Pharmacol.*; 55:1031–1036, (2003).
46. Chabra A, Shokrzadeh M, Naghshvar F, Salehi F and Ahmadi A. Melatonin ameliorates oxidative stress and reproductive toxicity induced by cyclophosphamide in male rat. *Hum Exp Toxicol*. 2013.
47. Lovejoy J.C. The influence of dietary fats in insulin resistance, *Current diabetes reports*; 2 (5): 430- 440, (2002).
48. Ronald S. Nutritional intervention with omega-3 fatty acids enhances tumor response to anti-neoplastic agents. *Chemico-Biological Interactions*, 162(2): 89–105, (2006).