



A DIAGNOSTIC DILEMMA ON CYTOLOGY - SPINDLE CELL VARIANT OF ANAPLASTIC CARCINOMA AND MEDULLARY CARCINOMA OF THYROID

Dr. MAMATHA K ¹, Dr. ARAKERI S U ² AND Dr. BHASWANTH P ^{*3}

^{1,2,3} Department of pathology, BLDEU's Shri B.M.Patil Medical College, Hospital & Research centre, Vijaypur.

ABSTRACT

Anaplastic thyroid carcinoma (ATC) is most aggressive malignancy with an incidence of 1 - 2%. It is common in sixth decade of life with female predominance. Fine needle aspiration (FNA) is an important tool and provides correct diagnosis of ATC in upto 90% of cases. On cytology, ATC shows high cellularity smears composed of pleomorphic population of cells in a necrotic background. The three main patterns of ATC are spindle cell, giant cell, and squamoid. Spindle cell variant should be differentiated mainly from medullary carcinoma of thyroid (MCT) & Malignant fibrous histiocytoma. The presence of amyloid in the smear is one of the distinguishing feature from MCT to ATC, but amyloid is not identified in all cases. Spindle cell variant of ATC may be indistinguishable from MCT when scant necrosis is present, but differentiation of the two lesions is important for further management. There should be a high index of suspicion for anaplastic thyroid carcinoma when areas of necrosis is present on cytology. Hence, we present a case of 60 year old female presented with midline neck swelling. Differential diagnosis of spindle cell variant of ATC and medullary carcinoma (MCT) was considered on cytology and confirmed as ATC with residual papillary carcinoma of thyroid (PCT) on histopathology.

KEY WORDS: Anaplastic thyroid carcinoma, Anaplastic transformation, PCT



Dr. BHASWANTH P

Department of pathology, BLDEU's Shri B.M.Patil Medical College, Hospital & Research centre, Vijaypur.

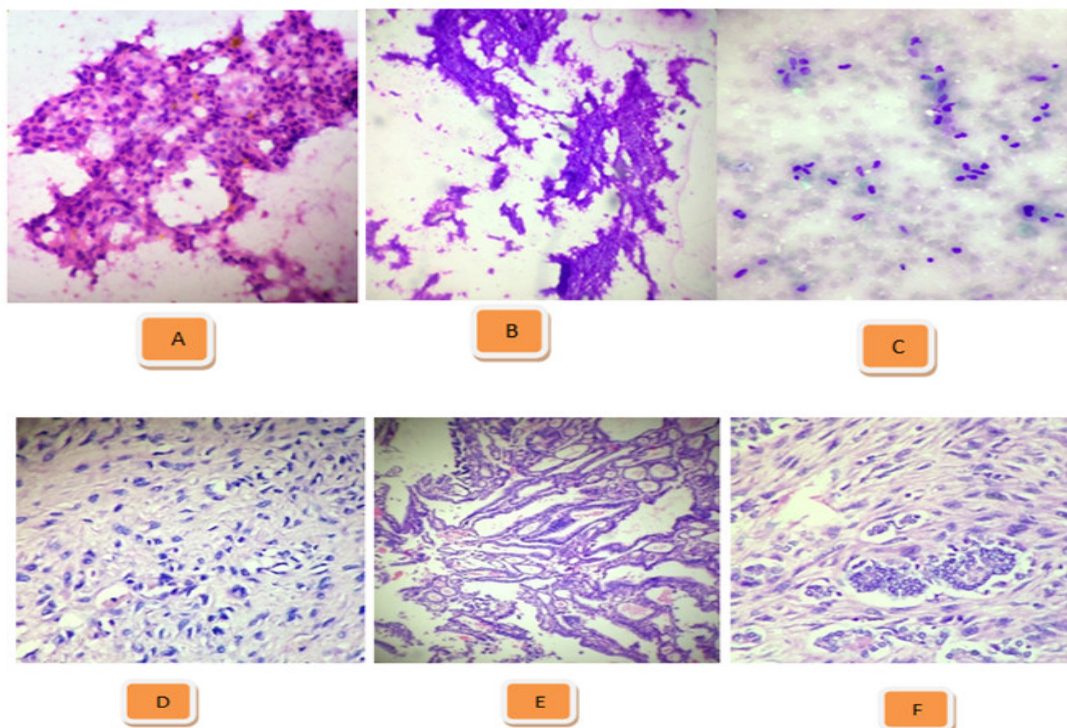
INTRODUCTION

Anaplastic thyroid carcinoma (ATC) is most aggressive malignancy with an incidence of 1 to 2%.¹ It is least common of all thyroid malignancies recognised clinically, but it accounts for more than half of the deaths for thyroid cancer.² The mortality rate is over 90% and a mean survival of six months after the diagnosis.² It is common in sixth decade of life with female predominance.² FNAC is an important tool and can provide correct diagnosis of ATC in upto 84% of cases.² Spindle cell variant of ATC may be indistinguishable from Medullary carcinoma thyroid (MCT) when scant necrosis is present, but differentiation of the two lesions is important in view of further management & prognosis.³ Here is a case of ATC which was diagnosed on fine needle aspiration cytology (FNAC) and further confirmed by histopathological examination.

CASE SUMMARY

A 60 year old female presented with midline neck swelling since 1 year was referred to the department of pathology for FNAC of the lesion. On examination swelling was diffuse measuring about 5x4x4 cm, soft to firm in consistency and moved with deglutition. FNA was performed using 22 G needle and 10 cc syringe. Smears were prepared and staining was done. Wet smears were stained with Hematoxylin & Eosin (H&E) & PAP stain. Air dried smears were stained with Giemsa. Multiple smears stained with H&E, PAP & Giemsa

showed high cellularity showing tumor cells arranged in sheets, small, large clusters & singly dispersed. Individual cells were spindle shaped having pleomorphic, hyperchromatic nuclei, abundant eosinophilic cytoplasm. Few cells showed plasmacytoid morphology & stippled chromatin. Also noted binucleated & multinucleated tumor cells. Background showed focal areas of necrosis & many RBCs. Correlating the clinical and cytologic features, differential diagnosis offered was Anaplastic thyroid carcinoma & spindle cell variant of medullary carcinoma, with suggestion of wide local excision. **MACROSCOPY:** We received a subtotal thyroidectomy specimen measuring about 6x5x4cm. External surface was irregular, nodules at places with areas of congestion. Cut section showed variegated appearance having solid, cystic & hemorrhagic areas. Solid areas were irregular, grey white measuring 3x3cm and cystic area measured 2x2cm and was filled with colloid. **MICROSCOPY:** Histopathological examination showed tumor tissue arranged in papillary, storiform and insular pattern. Individual tumor cells were highly pleomorphic, bizarre, round to oval with round to oval hyperchromatic nuclei and prominent nucleoli. Also seen spindle shaped cells with elongated hyperchromatic nuclei and few inconspicuous nucleoli. Also seen typical and atypical mitotic figures of 6-8/HPF. Focal areas of necrosis, calcification and a small focus of clear cell change were also noted. Based on these features we diagnosed it as Anaplastic carcinoma with residual papillary carcinoma of thyroid.



- (A) Microphotograph showing tumor cells in sheets (H&E Stain, x100)
 (B) Microphotograph showing necrosis (Giemsa Stain, x400)
 (C) Microphotograph showing singly scattered tumor cells (Giemsa Stain, x100)
 (D) Microphotograph showing bizarre and spindle shaped tumor cells (H&E Stain, x400)
 (E) Microphotograph showing tumor cells arranged in papillary pattern (H&E Stain, x100)
 (F) Microphotograph showing tumor cells showing nuclear clearing (H&E Stain, x400)

DISCUSSION

ATC is a highly malignant tumor. According to WHO, ATC is comprised of undifferentiated cells wholly or partially, but these cells retain features indicative of an epithelial origin.² On FNAC, ATC are highly cellular smears composed of a pleomorphic population of cells in a necrotic background.² The individual tumor cells are large, oval to spindle-shaped arranged in dyscohesive sheets and shows moderate anisocytosis.² These cells have single or multiple nuclei, reflects the sarcomatoid or epithelioid histological morphology.² The three main patterns of ATC are spindle cell, giant cell, and squamoid.² Spindle cell variant should be differentiated mainly from medullary carcinoma of thyroid (MCT) & Malignant fibrous histiocytoma.² Careful observation of cellular density, arrangement and individual cell morphology, presence of necrosis may help in differentiating these tumors. Compared to other soft tissue tumors, ATC aspirate will be more cellular and shows bizarre nature of tumor cells and abundant necrosis.³ Most of the cases of ATC are due to terminal dedifferentiation of pre-existing well differentiated thyroid carcinoma (WDTC). The progression of WDTC to ATC is due to the loss of P53 tumor suppressor gene. Demeter et al found 76% of ATC had previous or concurrent thyroid disorders, with 47% related to WDTC.⁴ The presence of amyloid in the smear is one of the distinguishing feature from MCT to ATC, but amyloid is

identified in 43-81% cases only.⁵ ATC is positive for cytokeratin, epithelial membrane antigen, vimentin but it is negative for calcitonin which helps in distinguishing from MCT.⁵ Treatment of ATC is multimodal approach with surgery, radiotherapy & chemotherapy due to the lack of effective medical treatment currently.⁶

CONCLUSION

To conclude Spindle cell variant of ATC may be indistinguishable from MCT when scant necrosis is present, but differentiation of the two lesions is important for further management.³ Hence, there should be a high index of suspicion for anaplastic thyroid carcinoma when areas of necrosis is present on cytology as preoperative cytological diagnosis may help the surgeon to give best possible treatment to their patients.

ACKNOWLEDGEMENT

We sincerely thank our Head of Department Dr.B.R.Yelikar for his continuous support and encouragement.

CONFLICT OF INTEREST

Conflict of interest is none.

REFERENCES

1. Sze-How NG, Imisairi AH. The Aggressive anaplastic thyroid carcinoma: A case report & institutional review. *World J Endocr Surg*, 2012;4(1):20-22.
2. Ragazzi M et al. Update on Anaplastic Thyroid Carcinoma: Morphological, Molecular, and Genetic Features of the Most Aggressive Thyroid Cancer *Int J of Endo*, 2014:1- 13.
3. Orell S, Sterett G, Whitaker D. *Fine needle aspiration cytology*. 4th ed. New Delhi: Elsevier; 2005, p.151-55.
4. Patel K, Shaha A. Poorly differentiated and anaplastic thyroid cancer. *Cancer control*, 2006; 13 (2): 119-128.
5. Mondal SK, Nag DR, Bandyopadhyay R. Spindle cell variant of medullary carcinoma of thyroid with nodal metastasis: Cytodiagnosis and diagnostic dilemma. *Thyroid Res Pract*, 2012;9:60-3.
6. Xing J, Bishop J, Mathioudakis N, Agrawal N, Tufano R. A Large Nonmetastatic Anaplastic Thyroid Cancer with Complete Thyroidal Confinement. *Case reports in medicine*, 2011: 1-5.