



RESEARCH ARTICLE

PATHOLOGY

**TOXICOLOGICAL EFFECTS OF CARBARYL ON HEMATOLOGICAL PROFILES
IN BROILER CHICKS**



Corresponding Author

SABINA KHANAM

Department of Zoology, D.G. College, civil lines, Kanpur-208001 (U.P.)

ABSTRACT

The objective of this work is assessment of the toxicological effects of carbaryl in the blood parameters of broiler chicks. Twenty day-old chicks were assigned to four treatments of 0mg/kgb.w. , 15mg/kgb.w. , 20mg/kgb.w. , and 25mg/kgb.w. of carbaryl. Total-red blood cell count (T-RBC) significantly increased in the carbaryl supplemented group. Insignificant decrease was found in mean corpuscular volume (MCV) and in mean corpuscular hemoglobin (MCH) in carbaryl treated groups. Insignificant increase was found in mean corpuscular hemoglobin concentration (MCHC) in carbaryl treated groups.



KEYWORDS

carbaryl supplementation, toxicology, hematology, broiler chicks

INTRODUCTION

Carbaryl (1-naphthyl-1-N-methyl carbamate) is a carbamate insecticide introduced in 1956 by Union carbide Corporation. The insecticide is used worldwide and is a substitute for some organochlorine pesticides (Ribera *et al.*, 2001).

Carbaryl frequently contaminates air, rain, and streams. Carbaryl is toxic to birds, fish, tadpoles, salamanders, shrimp, bees, and other animals. Small amounts have caused adverse effects. These effects include reduced production of eggs, reduced ability to run, deformed legs, reduced swimming speed, and mortality.

The International Agency for Research on Cancer has not classified carbaryl as to its carcinogenicity for humans due to inadequate animal studies (IARC, 1987).

Birds exposed to carbaryl for an extended period of time may produce fewer eggs, have a higher number of cracked eggs, and are less fertile (U.S.EPA, 2003). Soviet researchers showed that exposure to carbaryl reduced immunity to tetanus in laboratory animals (Street, 1981).

Carbaryl is absorbed through skin and ends up in a variety of tissues and organs. Scientists from the Institute of Agricultural Medicine (Poland) showed that carbaryl applied to skin of laboratory animals ended up in the liver, blood, and brain (Tós-Luty, *et al.*, 2001).

Hematology is often used to detect physiological changes following different stress conditions. Thus hematology can be considered as an essential index to the general health status (Blaxhall and Daisely, 1972).

MATERIALS AND METHOD

Experimental Animals: Twenty day-old broiler chicks (*Gallus gallus*) of weight ranging from 25-30 gm. were used in the experiment. Broiler Chicks were quarantified for 10 days and it was confirmed that they were free of pathogen and any other disease.

Broiler Chicks were kept in conventional condition (open system) and housed in stainless steel cages (800×14cm²) in animal house with room temperature 22±3°C, relative humidity 50-70%, photo period of 12 hrs. Light and 12 hrs. Dark. They were provided with commercial broiler chick starter diet and water ad libitum.

Experimental Procedure: The Chicks were distributed into four groups: one control group and three treated groups i.e. Low, Intermediate, and High dose. Control group was fed on the basal diet (commercial broiler chick starter diet) while all treated groups was supplemented with 15mg/kg b.w., 20mg/kg b.w. and 25mg/kg b.w. of carbaryl for 21 days.

HEMATOLOGICAL STUDIES: Blood was collected from wing vein into anticoagulant (EDTA) treated tubes for determination of hematological parameters. The following hematological parameters were assessed by using MS9 Fully Automatic Fully Digital Hematology Cell Counter. Version 3.5×E from Melet Schloesing Laboratories, France.

- Total-Red Blood Cell (T-RBC)
- Mean Corpuscular Volume (MCV)
- Mean Corpuscular Hemoglobin (MCH)
- Mean Corpuscular Hemoglobin Concentration (MCHC)



STATISTICAL ANALYSIS: Statistical analyses were performed using STATGRAPHICS 3.0 software. The data were analyzed using one-way ANOVA test. Results were presented as

mean±SE. The significance of difference among the groups was assessed using students t-test. Significance was set as $P<0.05$, $P<0.01$ and $P<0.001$.

RESULT

Table-1, Graph-1(a) illustrates RBC count in control and experimental groups of animals. On comparing with control statistically significant $p<0.005$ elevation was found in intermediate dose but insignificant $p>0.005$ decreases in RBC count was found in low dose and high dose as compared to control.

On comparing with the control in Table-1, Graph-1(b), statistically insignificant decrease was found in MCV in intermediate dose and in high

dose but insignificant increase was found in low dose as compared to control.

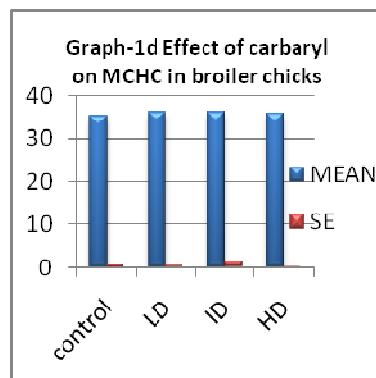
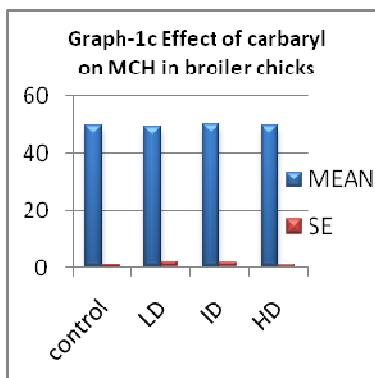
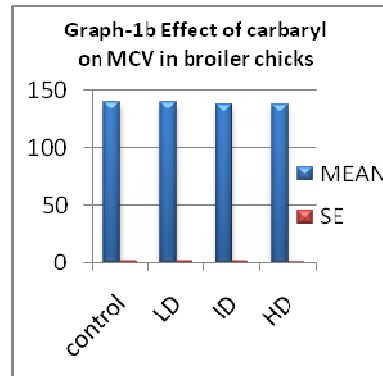
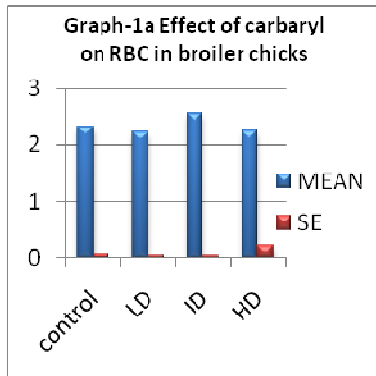
In the present study Table-1, Graph-1(c), shows non significant decrease was found in low dose as compared to control of MCH but was similar to control in intermediate dose and in high dose.

MCHC shows increase for low dose group, intermediate dose and high dose group as compared to control but $p>0.005$ for three treated groups Table-1, Graph-1(d).

Table-1
Hematological changes (Mean±S.E.) in broiler chicks exposed to different doses of carbaryl (n=5)

Parameters	Control	Low dose	Intermediate dose	High dose
RBC (Per cu mm)	2.32±0.07	2.22±0.05	2.57±0.05*	2.24±0.22
MCV (fl)	139.84±2.02	140.18±1.70	138.16±2.02	138.16±1.25
MCH (pg)	49.4±0.83	48.9±1.76	49.78±1.45	49.32±0.67
MCHC (g/dl)	35.32±0.57	36.04±0.79	36.1±1.22	35.7±0.21

Values are mean of experiments ± SEM with 5 chicks in each group. Those marked with asterisks differ significantly from the control values * $P<0.05$, ** $P<0.01$, *** $P<0.001$ (by ANOVA test).



DISCUSSION

Broiler chicks fed with carbaryl shows significant increase in RBC count of intermediate dose. Insignificant decrease was found in MCV and in MCH, but MCHC was increased in carbaryl treated groups. Contrary to our result in broiler chicks Decrease in various indices of blood after exposure to Sevin at different Concentrations indicated that *Clarias batrachus* became anemic. Organophosphate effect on hematological indices has been reported by Chindah *et al.*, (2004) in *Tilapia guineensis*. Anisocytosis and

crenation of erythrocyte membrane has been reported by Birendra *et al.*, (1991).

Dogs given chronic dose of carbaryl in their diet for 1 year exhibited no significant health effects when compared to control animals. However, carbaryl causes reversible fat deposition in the proximal tubules of the kidneys in exposed chickens, dogs, rats, and rhesus monkeys (Carpenter *et al.*, 1961; Wills *et al.*, 1968). Changes in blood cell profile have been reported in *Cyprinus carpio* due to the effect of diazinon by Svoboda *et al.*, (2001).

REFERENCES

1. Birendra Kumar; Banerjee V (1991). Effects of lethal toxicity of sevin (carbaryl) on the blood parameters in *Clarias batrachus* L.

Himalayan J Environ Zoo, 6 (1), 13-17 [30 Ref].



2. Blaxhall, P.C. and K.W. Daisley, 1972. Routine hematological methods for use with fish blood. *J.Fish Biol.*, 5:771-781.
3. Carpenter, C. P.; Weil, C. S.; Palm, P. E.; Woodside, M. W.; Nair III, J. H.; Smyth, H. F., Jr. Mammalian Toxicity of 1-Naphthyl-N-methylcarbamate (Sevin insecticide). *J. Agric. Food Chem.* 1961, 9, 30-39.
4. Chindah, A C; Sikoki, F D; Vincent-Akpu., I (2004). Toxicity of an organophosphate pesticide (chloropyrifos) on a common Niger Delta Wetland Fish- *Tilapia guineensis*. *J. Appl. Sci. Environ .Mgt:Vol.8 (2)* 11-17.
5. International Agency for Research on Cancer. *IARC Summary and Evaluation- Carbaryl*, Suppl. 7; WHO Geneva, Switzerland, 1987; Volume 12. <http://www.inchem.org/documents/iarc/vol12/carbaryl.html> (accessed Dec 2001).
6. Ribera, D., Narbonne, J.F., Arnaud, C., and Denis, M.S. (2001). Biochemical responses of the earthworm *Eisenia fetida* Andrei exposed to contaminated artificial soil, effects of carbaryl. *Soil Biol. Biochem.* Vol. 33, pp: 1123-1130.
7. Street, J.C. 1981. Pesticides and the immune system. In *Immunologic considerations in toxicology*. Vol. 1. R.P. Sharma, ed. Boca Raton FL: CRC Press. Pp. 45-66.
8. Svoboda, M; Luskova, V; Drastichova. Zlabek, V, 2001: The effect of diazinon on haematological indices of Common Carp (*Cyprinus carpio L.*). *Acta vet. BRNO*, 70: 457-465.
9. Tós-Luty, s. *et al.* 2001. Dermal absorption of distribution of ¹⁴C carbaryl in Wistar rats. *Ann. Agric. Environ. Med.* 8:47-50.
10. U.S. Environmental Protection Agency. Interim Reregistration Eligibility Decision for Carbaryl. Case 0080. http://www.epa.gov/oppsrrd1/REDs/carbaryl_ired.pdf (accessed Oct 2003).
11. Wills, J. H.; Jameson, E.; Coulston, F. Effects of Oral Doses of Carbaryl on Man. *Clin. Tox.* **1968**, 1, 265-271.